



Immunomodulatory and Toxicological Effect of Goya Extra Virgin Olive Oil in Albino Rat Orogastrically Dosed with *Salmonella typhi*

J. O. Aribisala^{1*} and M. K. Oladunmoye¹

¹*Department of Microbiology, Federal University of Technology, P.M.B. 704, Akure, Ondo State, Nigeria.*

Authors' contributions

This work was carried out in collaboration between both authors. Author JOA designed the study, performed the statistical analysis, wrote the protocol and wrote the first draft of the manuscript. Author MKO managed the analyses of the study. Both authors managed the literature searches. Both authors read and approved the final manuscript.

Article Information

DOI: 10.9734/JAMB/2017/37372

Editor(s):

(1) P. Rama Bhat, P G Biotechnology, Alva's College, Karnataka, India.

Reviewers:

(1) Bogumil E. Brycki, Adam Mickiewicz University, Poland.

(2) Ionica Mihaela Iancu, Banat University of Agronomical Sciences and Veterinary Medicine, Romania.

(3) Alberto de J. Oliveros Bastidas, Venezuela.

Complete Peer review History: <http://www.sciencedomain.org/review-history/21898>

Original Research Article

Received 13th October 2017
Accepted 8th November 2017
Published 14th November 2017

ABSTRACT

The immunomodulatory and toxicological properties of Goya extra virgin olive oil on albino rats orogastrically dosed with *Salmonella typhi* were evaluated in this study. Twenty albino rats were randomly distributed into four groups (A-D) of five rats each. The groups (B-D) infected with *Salmonella typhi*, revealed that the animals shows depressed activity and weakness characterised by slow movement. The rats in groups B were treated with olive oil, group C were treated with 20 mg ofloxacin, while Group A rats served as control and group D rats were left untreated. Group B and C rats were treated orogastrically with olive oil and ofloxacin daily for seven days. The total phenol derivative present in the olive oil which contributes to the observed inhibitory effect of the oil was 14.90 mg/g. At the end of the treatment period, haematological analysis of the groups infected and fed with olive oil (B) showed white blood cell count (WBC) to be within the normal range ($11.8 \times 10^3/\text{mm}^3$) indicating the immunomodulatory effect of olive oil. The WBC was least in value in

*Corresponding author: E-mail: jimexontop@gmail.com;

the control group (A) ($6.7 \times 10^3/\text{mm}^3$) and highest in the untreated group (D) whose WBC ($15.9 \times 10^3/\text{mm}^3$) was outside the normal range of WBC for an apparently healthy rat. The control group had the highest PCV (Packed cell volume) value of 56%, while olive oil to some extent help to modulate the PCV which can be revealed when the group treated with olive oil (52%) was compared with the untreated group (41.3%). Histopathological analysis shows liver of all infected group to have karyolysis and have cells that shows less prominent nucleus. The kidney of all the infected animals in group fed with olive oil (B) and those treated with antibiotics (C) shows infiltrations of cell, destruction of the glomerular tuft, and focal destruction of the renal tubules while The group left untreated (D) showed Tubular necrosis, vacuolation, destruction of the renal tubules, hyalinization, and degeneration of the glomerular tuft with possible infiltration of lymphocytes. The findings of this study revealed the non-toxic and immunomodulatory properties of olive oil, its suitability as an amazing food supplement that can improve human health and its efficacy as an alternative to antibiotics.

Keywords: Immunomodulatory; bioassay; *Salmonella typhi*; Goya extra virgin olive oil; orogastrically.

1. INTRODUCTION

Olive oil is pale yellow to greenish oil with a very distinctive flavour obtained from the pulp of olives by separating the liquids from solids. Olive oil was used in the ancient world for lighting, in the preparation of food, and as anointing oil for both ritual and cosmetic purposes. Olive oil is one of the most digestible of the edible oils and a good source of vitamin E [1]. Historically, the products of *Olea europaea* active components and clinical applications of olive oil have been used as aphrodisiacs, emollients, laxatives, nutritives, sedatives, and tonics. Specific conditions traditionally treated include colic, alopecia, paralysis, rheumatic pain, sciatica, and hypertension [2]. Olive oil's characteristic aroma, taste, colour, nutritive properties, and stability distinguish it from other edible vegetable oils. The positive influence of olive oil on health include an improvement in blood lipid profile by lowering the bad LDL-cholesterol (Low Density Lipoprotein) level while significantly raising the level of good HDL-cholesterol (High density Lipoprotein) in the blood stream. Olive oil consumption reduces coronary hearth diseases, diabetes, certain cancer risks such as breast, prostate and colon cancers, certain malignant tumours (endometrium, digestive tract, skin tumours) and some other chronic diseases [3]. Olive oil is believed to exert its biological benefits mainly via constituent antioxidants. Although the composition of olive oil is complex, the major groups of compounds thought to contribute to its observed health benefits include oleic acid, squalene, sterols (as β -sitosterol), polyphenols (tyrosol, hydroxytyrosol, oleuropein and many others), tocopherols, terpenoids, and traces of other constituents [3,4] all of which have been found to inhibit oxidative stress.

Recent advances have been made in the scientific understanding of how diet and specific foods within a balanced diet promote health and prevent illnesses. Not surprisingly, consumers are turning toward foods with medicinal properties as promising dietary interventions for disease prevention and health maintenance. As part of this trend, interests in the Mediterranean diet and specific foods that are integral to this diet have grown significantly. A common feature of the Mediterranean diet is a high consumption of olives and olive oil as the primary sources of dietary fat. In vitro studies have demonstrated the antimicrobial activity of hydroxytyrosol, Phenolic, tyrosol, and oleuropein against several strains of bacteria implicated in intestinal and respiratory infections. Phenolic compounds have been shown to inhibit the growth of *Escherichia coli*, *Klebsiella pneumoniae* and *Staphylococcus aureus* [5]. Oleuropein has been shown to inhibit sporulation of *Bacillus cereus* [6]. Hydroxytyrosol is a powerful antioxidant that has been the subject many research studies and has shown several biological properties, particularly anti-inflammatory, antifungal, antiviral and antibacterial activities. Hydroxytyrosol resulted effective against clinical human pathogenic strains of *Haemophilus influenzae*, *Moraxella catarrhalis*, *Salmonella typhi*, *Vibrio parahaemolyticus* and *S. aureus* [7]. Increasing resistance to antibiotics, wide-spread use of immune-suppressing drugs and a rise in bacterial infections emphasize the necessity to find and develop new antimicrobial agents. Hence, this present work is therefore aimed at providing relevant information on the immunomodulatory, toxicological and physicochemical properties of Goya extra virgin olive oil.

2. MATERIALS AND METHODS

2.1 Animal's Treatment and Diet

Handling and treatment protocols of animals were strictly adhered to as laid down in the ethical guide rules. Twenty adult albino rats weighing between 60 and 120 g were obtained from Iwo Osun State, Nigeria and used for this research. The animals were transported to the department of microbiology, Faculty of science, Federal university of technology Akure, Akure Nigeria. They were randomly assigned into four study groups of five rats per group. They were housed in woody cages with wire screen top and kept under adequate ventilation and environmental temperature. The animals were maintained on a commercial rat chow with tap water and food (finisher) provided to the rats and following acclimatisation and infection, a group of the infected rat were treated with Goya extra virgin olive oil (a product of Goya Andalucía manufactured in Espana Spain which was purchase from Nao supermaket Oja Oba market Akure, Ondo State, Nigeria).

2.2 Preparation of Inoculant for Infectivity of the Animal

Aseptically with the aid of a sterile inoculating loop, a pure strain of the test organism was picked from a preserved slant culture and inoculated into a sterile nutrient broth solution (nutrient agar solution whose gelling factor had been decanted out). The broth culture was shaken thoroughly to ensure even distribution of the organism in the broth. The broth culture was then incubated at 37°C for 24 hours after which the broth culture was centrifuged in a centrifuge so as to harvest the pure decanted cells. The pure cells were further washed by adding sterile water to the sediments and re- centrifuge for 3 more times. The resultant residue cell was obtained by decantation and was transferred into a sterile specimen bottle which was filled up to the 10 ml mark with sterile water for infectivity. 1 ml of the prepared organism was ingested orally into the rat with the aid of a syringe.

2.3 Infectivity Assay and Treatment

Following acclimatisation for one week, Animals in groups B to D were infected with the prepared inoculant of *Salmonella typhi* and the rats were left without food for 24 hours so as to enhance infectivity. While those in group A were left uninfected (control) and given normal feed. After three days of infection, Group B were fed with

olive oil in which 1 ml of the olive oil was ingested orally into the rat daily, group C were treated with antibiotics (ofloxacin) in which 200 mg of the antibiotics was dissolve in 10 ml of sterile water and 1 ml of the dissolve drug ingested orally into the rat daily for seven days, and group A and D while left untreated with neither olive oil nor antibiotics.

2.4 Haematological Assay

The animals were sacrificed and their blood was collected by cervical collection into labelled EDTA bottles. Haematological parameters were determined using the methods describe by [8].

2.5 Histopathology Analysis

One rat per group were removed and anaesthetised in chloroform vapour and dissected. The liver and kidney of the rat were removed and fixed in 10% formalin to prevent decay. They were dehydrated in different percentage (50%, 60%, 70%, 80%, 90%, and 100%) of alcohol for one hour 30minute each. After dehydration they were cleared with 100% xylene and left for 2 hours to remove any remnant alcohol and impregnated in liquid wax for 2 hours for embedding. The embedded organs were sectioned using microtome and were stained with haematoxylin- eosin. Excess stain was removed with tap water. After clearing in xylene, Canada balsam was added and cover slips placed on the slide. The preparations were left in the oven at 40°C and then placed under the microscope with a digital camera connected to a computer system to be examined by an expert and take the photographs [8].

2.6 Mineral Analysis

The oil samples were analysed for mineral content present in them using the method described by [9], the minerals were analysed from solution obtained by first drying 3 g of the oil sample on hot plate, they were transferred to muffle furnace for two and half hours at 75°C. After it has been cooled down in a desiccator, 2 ml of Aquaregia was added to dissolve the ash. Using distilled water it was made up to the 50 ml mark using distilled water. The values of the mineral contents are read on the atomic absorption spectrophotometer. Atomic absorption is a very specific technique and to avoid any major interference, an ultrapure water (Millipore) was used also since Most reagent grade acids contain some metallic impurities in trace amounts, an acid blank was run to

compensate for this problem. The detection limit was calculated using:

$$\text{Detection Limit} = \frac{\text{Standard Conc.} \times 3 \text{ Std. Dev.}}{\text{Mean}}$$

The calculation was made independently for each standard concentration, and the detection limit is the average of the two results.

2.7 Phytochemical Screening

The total phenol content of the olive oil was determined by the method of [10].

2.8 Statistical Analysis

All data were presented as mean \pm SEM. The one way ANOVA was used to analyse the data, followed by a post-hoc test (LSD). The results were considered significant at p values of less than 0.05.

3. RESULTS

3.1 Haematology Results

The results of the effects of Goya extra virgin olive oil on red blood cell count, white blood cell count, packed cell volume and haemoglobin concentration of albino rat orogastrically dose with salmonella typhi are shown in Table 1. The control group and the group fed with olive oil had a packed cell volume PCV of (56 \pm 3.32%) and (52.7 \pm 3.68%) respectively which was higher than the untreated and the group treated with ofloxacin. The white blood cells count of the control group (6.7 \pm 0.26 \times 10³/mm³), the group treated with ofloxacin (10.0 \pm 1.07 \times 10³/mm³)

and the group fed with olive oil (11.8 \pm 0.70 \times 10³/mm³) were found to be lower than the untreated group which was 15.9 \pm 1.10 \times 10³/mm³ while the Haemoglobin of the control group and the group fed with olive oil were higher than the untreated group. The result of the white blood differential; lymphocyte, neutrophil, monocyte, eosinophil, and basophil of the control group, group fed with olive oil, group treated with ofloxacin and the untreated group are shown in Table 1. When compared with other groups, the untreated group have the highest and lowest number of lymphocyte and neutrophil count respectively.

3.2 Histopathology Result

The result of the liver histopathology showed that the animals in the control group have normal liver structure in which the cells are in order and the hepatic sinusoids(S) separating the hepatic cord are in place lined by Kupfer cells. All the infected animals in the other group showed karyolysis (the whole cell stain uniformly) of the nucleus structure and have some cells with less prominent nucleus (Fig. 1). The untreated group remain the only group that have their sinusoid to have been greatly diffused. The kidney of the control group showed normal kidney structure without any deformation. All the infected animals in group B and C showed infiltrations of cell, destruction of the glomerular tuft, and focal destruction of the renal tubules. The group left untreated showed Tubular necrosis, vacuolation and destruction of the renal tubules, hyalinization and degeneration of the glomerular tuft with possible infiltration of lymphocyte (Fig. 2).

Table 1. Haematological parameters of the animal's blood

Group	ESR (mm/hr)	PCV (%)	WBC \times 10 ³ /mm ³	RBC \times 10 ⁶ /mm ³	Hb g/dl
Group A	1 \pm 0.00	56 \pm 3.32	6.7 \pm 0.26	6.7 \pm 0.39	18.7 \pm 1.16
Group B	3 \pm 0.82	52.7 \pm 3.68	11.8 \pm 0.70	6.6 \pm 1.06	17.7 \pm 1.24
Group C	2 \pm 1.00	50.3 \pm 3.40	10.0 \pm 1.07	9.97 \pm 1.32	16.7 \pm 0.79
Group D	5 \pm 0.58	41.3 \pm 3.4	15.9 \pm 1.10	9.4 \pm 0.93	13.7 \pm 1.00
	Lymphocyte	Neutrophil	Monocyte	Eosinophil	Basophil
Group A	63 \pm 2.94	24 \pm 1.30	11 \pm 1.92	2 \pm 0.82	1 \pm 0.00
Group B	64 \pm 3.32	26.6 \pm 2.49	10 \pm 1.63	2 \pm 0.58	0.3 \pm 0.40
Group C	63 \pm 1.41	24.7 \pm 1.98	8 \pm 0.58	3 \pm 0.58	1 \pm 0.00
Group D	67 \pm 2.52	19 \pm 2.12	9 \pm 2.16	3 \pm 0.82	0.3 \pm 0.40

where, ESR= Erythrocyte, PCV= Packed cell volume, WBC= White blood cell, RBC= Red blood cell, and Hb= Haemoglobin

Group A: Control group, Group B: Group infected and fed with olive oil, Group C: Group infected and treated with antibiotics, and Group D: Group infected and left untreated

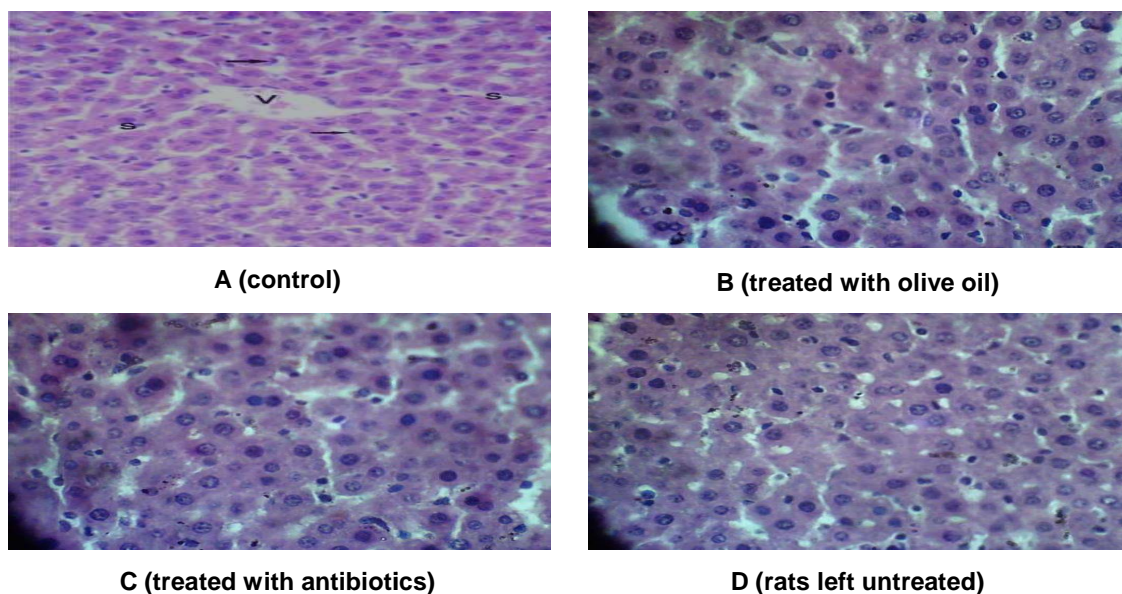


Fig. 1. Effect of various treatments on histopathology of the liver

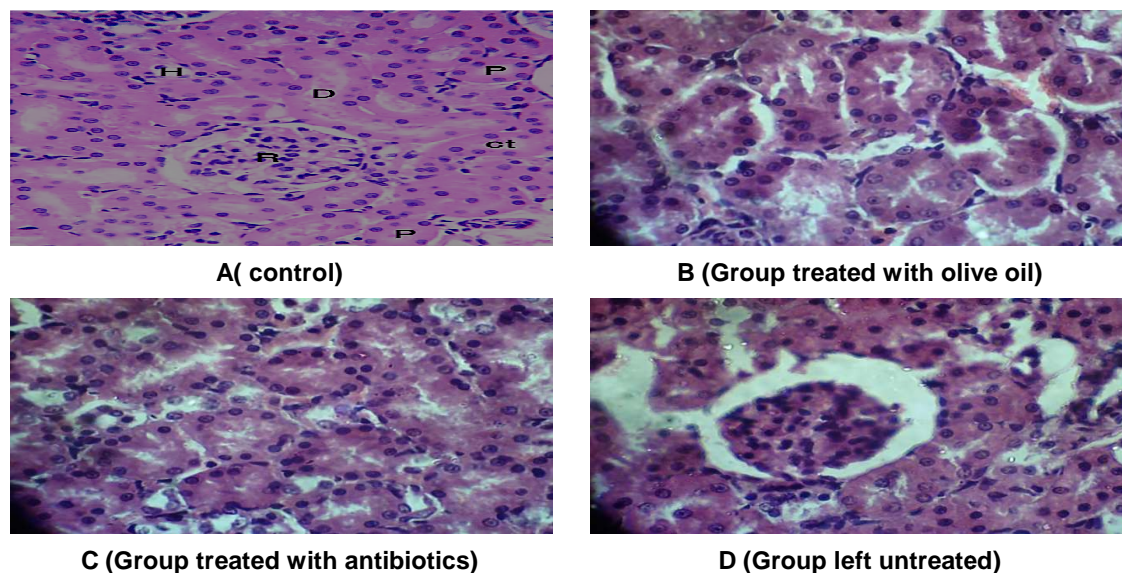


Fig. 2. Effect of various treatments on histopathology of the kidney

3.3 Physicochemical Analysis Result

The result of the physicochemical analysis of the Goya extra virgin olive oil was shown in Table 2.

3.4 Mineral Analysis Result

The result of the mineral analysis of the Goya extra virgin olive oil was shown in Table 3. It was noted that no traces of lead was present.

Table 2. Physicochemical properties of the olive oil

Parameter	Result
Specific gravity(g/cm ³)	0.91 ± 0.02
Acid value (mg/g)	2.72 ± 0.033
Free fatty acids (mg/g)	1.36 ± 0.09
Peroxide value (mg/kg)	18.80 ± 0.01
Saponification value	173.77 ± 0.31

Table 3. Minerals properties of the olive oil

Parameter	Result (ppm)
Pb	BDL
Fe	0.02
Zn	0.43

BDL = below detection limit

3.5 Phytochemical Result

The total phenol content present in Goya extra virgin olive oil was 14.90 ± 0.189 mg/g.

4. DISCUSSION

The control group had the highest PCV value of 56% meaning that there are 56 millilitres of cells per 100 millilitres of blood, while olive oil to some extent help to modulate the PCV which can be revealed when the group treated with olive oil (52%) was compared with the untreated group (41.3%). The WBC were least in value in control group ($6.7 \times 10^3/\text{mm}^3$) and highest in the untreated group whose white blood cell count ($15.9 \times 10^3/\text{mm}^3$) was outside the normal range of white blood cell for an apparently healthy rat which was given to be within ($6.6 \times 10^3/\text{mm}^3 - 12.6 \times 10^3/\text{mm}^3$) according to [11]. This increased value may be due to infection in the rat since white blood cells are produce to fight against infection and this agrees with the view of [12] who showed white blood cell to increase during active infection. The white blood cell of group fed with olive oil ($11.8 \times 10^3/\text{mm}^3$) is within the normal range of white blood cell for an apparently healthy rat but higher when compare with the control group indicating the fact that olive oil help to modulate the white blood cell. The Haemoglobin in the red blood cell of the group fed with olive oil (17.7 ± 1.24 g/dl) was higher than the group treated with ofloxacin and the untreated group (13.7 ± 1.00 g/dl) indicating the fact that olive oil have to favourable effect on haemoglobin whose function is to efficiently carries oxygen from the lungs to the tissues of the body. This is further augmented by the mineral analysis which shows that olive oil contains iron (Fe) and about 70% of the body's iron is found in the haemoglobin. The lymphocyte is higher in the untreated group which may be due to infection in the rat since lymphocytes are produce in response to infection [12]. The small amount of neutrophil recorded in the untreated group may be due to a numbers of neutrophils used up during the first few days of infection since neutrophils are the

first set of white blood cells that come into play immediately or within hours of an antigen's appearance in the body. The neutrophils were slightly higher in the group treated with olive oil compared to the group treated with antibiotics. Olive oil has been known to stimulate phagocytosis an action in which immune cells engulf and destroy microbes [13]. The body already support phagocytosis, but olive oil help to increase the activity of phagocytosis. The primary mode of action of olive oil in the body is through antimicrobial effect, olive oil fight harmful microbe and boosts the immune system. The exact mechanisms for antimicrobial effect in the body varies but include interference with critical amino acid production essential for bacteria replication, inactivation of bacteria through prevention of their budding or assemblage at the cell membrane, and direct penetration of cell wall in bacteria [14]. The high value recorded in ESR (5 mm/hr) for the untreated group may due to inflammation in the rat which causes the clumping together of the red blood cells and thus make them sink more quickly [11]. ESR for olive oil was 3 mm/hr which was smaller than that of the untreated group. A number of compounds in olive oil such as oleuropein, hydroxytyrosol, and tyrosol inhibit the inflammation mediator's nitric oxide and prostaglandin E_2 thereby offering excellent reduction of inflammation [13].

The result of the liver histopathology showed the animals in the control group to have normal liver structure in which the cells are in order and the hepatic sinusoids separating the hepatic cord to be in placed lined by Kupfer cells. This agrees with the work of [15] who showed that the liver histopathology of an apparently healthy rat to have normal liver structures. All the infected animals in the other group showed karyolysis which is the complete dissolution of the chromatin of a dying cell due to enzymatic degeneration. They also have some cells with less prominent nucleus that is; they have their boundaries to be less distinct. Karyolysis and the less prominent nucleus shown by the infected animals may be due to necrosis which is caused by factors external to the cell or tissue, such as infection in the animals. Cellular death due to necrosis does not follow the apoptotic signal transduction pathway, but rather various receptors are activated, and result in the loss of cell membrane integrity and an uncontrolled release of products of cell death into the extracellular space [16]. The untreated group remain the only group that have their sinusoid to

have been greatly diffused which may be due to the serious infection in this group since they were not given any form of treatment. The kidney of the control group showed normal kidney structure without any deformation which is in conformity with the work of [15] who showed kidney of apparently healthy rat to have normal histological structure of the renal corpuscle and renal tubules. All the infected animals in groups fed with olive oil and those treated with antibiotics showed infiltrations of cell (entering of fluid into the cell), destruction of the glomerular tuft, and focal destruction of the renal tubules which may be due to infections in these animals before treatment. Systemic and renal infections may lead to infiltrations of cell and inflammatory glomerular diseases [17]. The group left untreated showed Tubular necrosis which means death of the tissue of the kidney tubules, vacuolation, destruction of the renal tubules, hyalinization a condition in which normal tissue deteriorates into homogenous translucent materials, and degeneration of the glomerular tuft with possible infiltration of lymphocyte indicating the fact that the animal in the group are seriously infected since they received no form of treatment. This concurs with the view of [17] who shows that infections may lead to glomerular basement membrane damage resulting from immune deposits in the capillary wall, accumulation of IgA complexes in the glomerulus (IgA nephropathy) and others such as vasculitic glomerulonephritis. Glomerulonephritis involves glomerular inflammation.

The specific gravity of Goya extra virgin olive oil was found to be 0.91 which expresses how bulky or thick or light the oil is. The free fatty acid which is a chemical parameter of the oil and a broad indicator of its quality was found to be 1.36 mg/g. Recent research has concluded that the fatty acids in the make-up of olive oil are good allies in lowering important immunological parameters such as the proliferation of lymphocytes induced by specific mitogens of both B- and T-cells. These fatty acids have been reported to play an important part in various immune functions [18]. Oleic acid a fatty acid which acquired its name from olive oil is the most desirable nutritionally. Linolenic acid, with three double bonds, is the most chemically reactive and therefore undesirable from the view of stability. Palmitic acid is a saturated fatty acid and is also undesirable hence Olive oil with high oleic acid is nutritionally preferable and potentially more stable than low oleic olive oil

[19]. The acid value obtained (2.72 mg KOH/g) showed that the oil is edible since the value fall below maximum acceptable value of 4.0 mgKOH/g for oil as recommended by Codex Alimentarius Commission for oil [20] the value also shown that it is not prone to spoilage by oxidation (rancidity). The saponification value was 173.77 mg/ml and as such cannot be used as soap making. Oil with a saponification value of 200 mgKOH/g and above is regarded as high molecular weight fatty acid oil and is used in making of soaps [20]. Saponification value is a measure of the equivalent weight of acid present and therefore it is an indication of purity. The peroxide value which is used as an indicator of deterioration of oils was found to be 18.80 mg/kg this value is relatively low compared with the peroxide values of other oils of wild plants [19].

The total phenol derivatives present in Goya extra virgin olive oil was 14.90 mg/g. They are the major groups of compounds thought to contribute to the observed inhibitory effect of olive oil they include tyrosol, hydroxytyrosol, oleuropein and many others. Phenolic compounds have also been shown to inhibit the growth of *Escherichia coli*, *Klebsiella pneumoniae* and *Staphylococcus aureus* [5]. Polyphenol are strong antioxidant hence, olive oil can serve as exogenous source of antioxidant to complement the endogenous source in the body. Polyphenol are important for stability as well as the flavour characteristics of bitterness and pungency in olive oil.

The mineral analysis of the oil reveals the oil to be free of lead which can cause lead poisoning in human. And the presences of iron in the oil augment the reason why haemoglobin in the red blood cell of the group fed with olive oil was higher than the group treated with ofloxacin and the untreated group since about 70% of the body's iron is found in the haemoglobin. The presence of zinc in the oil further contribute to the reason why olive oil has immunomodulatory properties since zinc is needed for the body's defensive (immune) system to work properly.

5. CONCLUSION

The information presented in this study is on the immunomodulatory, toxicological, and physicochemical activities of Goya extra virgin olive oil. The investigated oil expressed a significant capacity to modulate certain immune

system, and thus can be used as an amazing health building supplement which stimulates immune system to fight against infection. The investigated oil also showed that olive oil has favourable effect in inhibiting the histopathological changes of the liver and kidney in *salmonella* dosed rat hence indicating the fact that the oil is non-toxic. Therefore, the oil has been proven as a non-toxic immune modulator that should be encouraged in our daily diet.

COMPETING INTERESTS

Authors have declared that no competing interests exist.

REFERENCES

- Owen RW, Haubner R, Wurtele G. Olives and olive oil in cancer prevention. *Eur J Cancer Prev.* 2004;13(4):319-26.
- Gilani AH, Khan AU, Shah AJ. Blood pressure lowering effect of olive is mediated through calcium channel blockade. *Int J Food Sci Nutr.* 2005;56(8): 613-20.
- Owen RW, Mier W, Giacosa A. Phenolic compounds and squalene in olive oils: The concentration and antioxidant potential of total phenols, simple phenols, secoiridoids, lignans and squalene. *Food Chem Toxicol.* 2000;38(8):647-59.
- Covas MI, Torre K, Farre-Albaladejo M, Kaikkonen J, Fito M, Lopez-Sabater C. Postprandial LDL phenolic content and LDL oxidation are modulated by olive oil phenolic compounds in humans. *Free Radic Biol Med.* 2006;40(4):608-16.
- Fabiani R, Bartolomeo A, Rosignoli P. Cancer chemoprevention by hydroxytyrosol isolated from virgin olive oil through G1 cell cycle arrest and apoptosis. *Eur J Cancer Prev.* 2002;11(4): 351-8.
- Tassou CC, Nychas GJ. Effect of phenolic compounds and oleuropein on the germination of *Bacillus cereus* T spores. *Biotechnol. Appl. Biochem.* 1991;13(2): 231-7.
- Bisignano G, Tomaino A, Lo-Cascio R, Crisafi G, Uccella N, Saija A. On the *in-vitro* antimicrobial activity of oleuropein and hydroxytyrosol. *J. Pharm.Pharmacol.* 1999;51(8):971-4.
- Bamidele O, Akinnuga AM, Olorunfemi JO, Odetola OA, Oparaji CK, Ezeigbo N. Effects of aqueous extract of *Basella alba* leaves on haematological and biochemical parameters in albino rats. *Afr J Biotechnol.* 2010;9(41):6952-6955.
- Omotosho OE, Laditan OC, Adedipe OE, Olugbuyiro JAO. Effect of deep-fat frying on the vitamins, proximate and mineral contents of *Colocasia esculenta* using various oils. *Pakistan J Biol Sci.* 2015;18(6):295-299.
- AOAC. Official methods of analysis. Association of official analytical chemists. 19th Edition, Washington D.C; 2012.
- Johnson DC. Exotic animal companion medicine hand book for veterinarians, zoological education network ferrets, rabbits and rodents. 2nd Edition Queensberry and Carpenters; 1996.
- Alberts B, Alexander J, Julian L, Martin R, Keith R, Peter W. Leukocyte functions and percentage breakdown. *Molecular biology of the cell.* 4th Edition Garland Science New York; 2002.
- Tuck KL, Hayball PJ. Major phenolic compounds in olive oil: Metabolism and health effects. *J Nutr Biochem.* 2002;13(11):636-644.
- Falkow SK, Denise M, Mueller A. Persistent bacterial infections: The interface of the pathogen and the host immune system. *Nature Rev Microbiol.* 2004;2(9):747-65.
- Sharma SD, Iqbal M. Lithium induced toxicity in rats: A hematological, biochemical and histopathological study. *Biol Pharm Bull.* 2005;28(5):834-7.
- Proskuryakov SY, Konoplyannikov AG, Gabai VL. Necrosis: A specific form of programmed cell death? *Exp. Cell Res.* 2003;283(1):1-16.
- Nangaku M, Couser WG. Mechanisms of immune-deposit formation and the mediation of immune renal injury. *Clin Exp Nephrol.* 2005;9:183-191.
- Aigbodion AI, Okieiman FE. Proceedings of the 27th International Conference of the Chemical Society of Nigeria, Held at Benin, Nigeria; 2004

19. Sergio L, Beatriz B, Yolanda MP, Almudena O, Lourdes MV, Rocio A. olives and olive oil in health and disease prevention, cellular and molecular nutrition, Instituto de la Grasa (CSIC), Seville, Spain. 2010;1385–1393.
20. Inekwe UV, Odey MO, Gauje B, Dakare A, Ugwumma C, Adegbe E. Fatty acid composition and physicochemical properties of *Jatropha curcas* oils from Edo and Kaduna states of Nigeria and India. Annals Biol. Sci. 2012;3:4860-4864.

© 2017 Aribisala and Oladunmoye; This is an Open Access article distributed under the terms of the Creative Commons Attribution License (<http://creativecommons.org/licenses/by/4.0>), which permits unrestricted use, distribution, and reproduction in any medium, provided the original work is properly cited.

Peer-review history:

The peer review history for this paper can be accessed here:
<http://sciencedomain.org/review-history/21898>