

One Injury, Two Tracks and Two Weapons with Two Thoughts: An Exhumation Case Report

NAVEEN SHARMA¹, KUNAL KHANNA², VIJAY PAL KHANAGWAL³, LUV SHARMA⁴, JITENDER KUMAR JAKHAR⁵



ABSTRACT

Exhumation is authorised digging out of already buried body from his legitimate graveyard. The autopsy in exhumed dead body require extreme attention and thorough examination of the corpse to determine the exact cause and manner of death. Exhumation also helps to evaluate and rule out any disease responsible for death. In the present case, authors discuss and report an unusual case of decomposed young adult male of 24-year-old, who was killed/stabbed by his younger brother. Body of deceased was buried by the perpetrator of crime without police information and medicolegal autopsy. The stab wound was altered by accused to misguide or create confusion in identifying the type of injury and weapon of offence. Later, this scenario was solved by autopsy surgeons after visiting incident scene, complete postmortem examination of the corpse and examinations of belongings.

CASE REPORT

Dead body of a 24-year-old, unmarried man with alleged history of stab injury was referred to mortuary of Government medical college for postmortem examination. On history given by the next of kin and investigating police officer, it was known that the deceased was stabbed by his younger brother following a quarrel. The relatives did not file a case in police station because of fear of death and accused was a family member. The body was buried stating it as a natural death. Soon after, the elder brother of the deceased came from abroad and visited the home of the deceased. He observed reddish hue on the marble of the floor and found a blood soaked cotton ball behind the door. On account of suspicion, he filed a case in police station stating that the deceased was stabbed by his younger brother. On the request of the elder brother of deceased, the executive magistrate ordered the exhumation. The body was exhumed on fourth day of burial in early morning in the presence of a magistrate and a forensic expert. The corpse was brought for postmortem examination on same day. No weapon of offence was recovered from the grave.

Upon opening the grave, it was three feet deep and the corpse was found wrapped in a white coloured cloth. This was extracted and sent to the Forensic Department for examination. The soil was soaked in reddish fluid at places [Table/Fig-1].



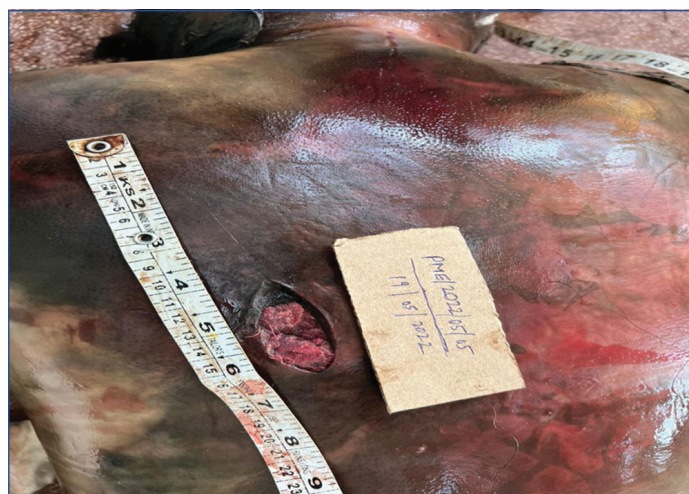[Table/Fig-1]: Depicting reddish stains on soil at places and grave of deceased.

Autopsy Findings

On external examination, the body was naked and found to be wrapped in a white coloured piece of cloth. Signs of decomposition

Keywords: Autopsy, Burial, Digging out, Homicide, Stab wound

were established. A wedge shaped stab wound of size 6x2.5x8 cm was present obliquely over left side of lower chest wall situated 6 cm left to midline and 137 cm above to left heel. The wound was filled with cotton [Table/Fig-2].

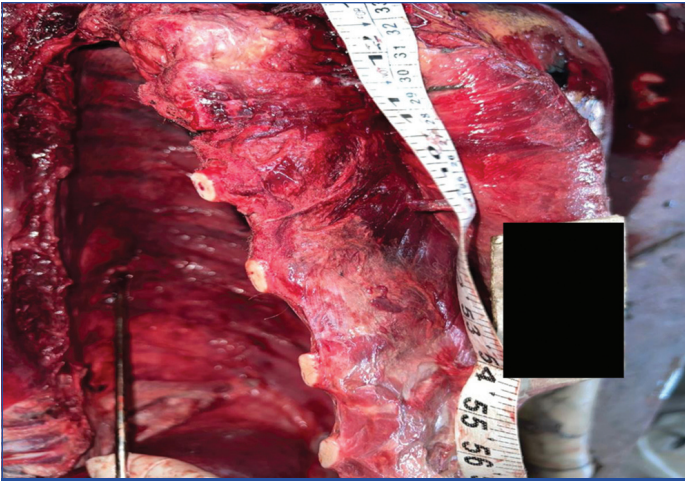


[Table/Fig-2]: Depicting a wedge-shaped wound with clean cut margins and cotton inside the wound.

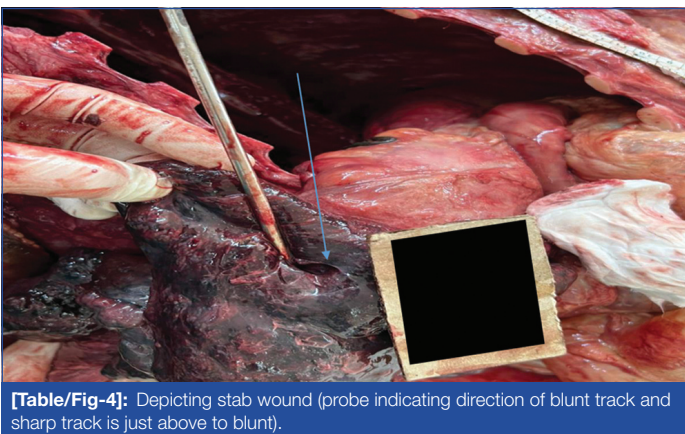
On opening of thoracic cavity, left pleural cavity was filled with 750 mL liquid blood and superior surface of eighth rib of left side in paravertebral region showed sharp cut with infiltration of blood in its bony trabeculae. On further exploration, lower lobe of left lung was found collapsed. On exploration, the skin and underlying soft tissues were found clean cut with extravasation of blood in the underlying and surrounding tissue [Table/Fig-3].

The track was clean cut and going downward, forward and medially with extravasation of blood. On dissection of track, another blunt track was found in the posterior wall of sharp track and which went upward and forward and the lung parenchyma was found lacerated in this track without any extravasation of blood [Table/Fig-4].

Brain, liver, spleen and both kidneys were found softened and putrefied. The stomach contained 150 mL reddish brown liquid fluid with putrefactive changes. The cause of death in this case was opined as stab injury described and its complications, which



[Table/Fig-3]: Depicting tear in pleura and intercostal muscles with extravasation of blood in muscles.



[Table/Fig-4]: Depicting stab wound (probe indicating direction of blunt track and sharp track is just above to blunt).

is antemortem in nature and homicidal in manner. Chemical examination report of viscera was negative for any poison including alcohol.

Thus, there was one stab injury over the body, on examination of which, there were two tracks i.e., sharp and blunt. The sharp was due to a knife stab and the blunt track was due to a metallic probe. The assailant had stabbed with a thought to kill the deceased and later cotton was inserted in the wound to stop the bleeding from wound or to conceal the crime committed by him.

DISCUSSION

The success of any exhumation depends not only on the technical means available to accomplish the requested mission, but also on the conservation conditions of the corpse like duration of burial, conditions of soil, confined or unconfined body and various environmental factors [1]. Traditionally, exhumations have been performed to permit autopsy or reautopsy to determine cause of death for criminal and civil litigation purpose [2].

Incidences of exhumation is variable in the world and depends on various factors like cultural, political and religious convictions. It is less common in India. Unlike many other countries that have a well-defined time limit up to which exhumation can be done, in India there is no time limit for ordering the exhumation [3]. In India, exhumation is done only when, there is written order from Executive or Judicial Magistrate 176 (3) CrPC but in countries like United Kingdom (UK), United States of America (USA) coroner and medical examiner can order for exhumation [4].

Exhumation helps in fixing the identity of an individual and helps in solving the unresolved crime cases. If done meticulously with the use of modern ailments, in difficult scenarios, it helps in fixing the

identity and cause of death and innocence of suspected persons may be proved [5]. Decomposition makes it difficult to examine the body itself and alter the findings as well. Non forensic exhumations are also performed when bodies or cemeteries must be moved from one place to other and to examine long buried remains for academic purposes [4].

Similar to present case, Jatti VB et al., reported a case, in which the deceased was buried without postmortem examination, stating accidental death by the next of kin. In their case, the exhumation was done after two months of burial. After autopsy, forensic expert opined the cause of death in that case as fatal stab injury [5].

Akhiwu WO and Nwafor CC reported a study on exhumation and they found the cause/manner of death in 63.8% of total exhumed bodies. They concluded from their study that whenever the need arises, exhumation and postmortem examination should be done in a buried body [6]. Selvaraja GR et al. reported a case of multiple stab injury. They found that, various features of like location, shape and direction of the wounds could be important to differentiate suicide from homicide [7]. These features also helped the authors to ascertain the manner of death in the present case. Rani M et al., reported a case of a child in which body was buried after committing sexual assault and strangulation. After the passage of about two years the victim's body was exhumed. In that case, the body of the victim was identified by mother from a small piece of under slip and other worn articles [8]. In the present case, body was naked and body was not identifiable and authors preserved a long bone for confirmation of identity by Deoxyribose Nucleic Acid (DNA) matching.

In the present case, after complete postmortem examination, crime scene visit report and alleged weapon examination, the authors were able to conclude that the cause of death in the present case was fatal stab injury and its complications which was homicidal in manner. After stabbing with a knife on the back the perpetrator of crime had inserted cotton in the wound with the help of metallic probe. Inflicted sharp injury was due to blow by sharp edge knife (homicide) and blunt track was raised (accidental) due to metallic probe hence, this indicates that the accused inflicted both the injuries with two different intentions.

CONCLUSION(S)

A meticulous forensic autopsy may answer the queries of investigating agencies and judiciary related to the cause, manner of death, revealed or fixing the identity of deceased and it act as an aid for justice to departed soul. Further, careful comparison with other details from the crime scene and information from the witnesses helps to recreate the scene of crime. In light of the above, even without a formal conclusion, exhumation brought great satisfaction to the next of kin.

REFERENCES

- [1] Baden MM, Spitz WU (ed). Exhumation. *Medicolegal Investigation of Death*. 4th ed. Charles C Thomas Publisher Ltd. 2006 USA. Pp.174-183.
- [2] Knight B, Saukko P. *The Forensic Autopsy*. Knight's Forensic Pathology. 4th ed. 2016. CRC Press. USA. Pp. 40-42.
- [3] Reddy KSN, Murty OP(ed.) *Medicolegal Autopsy*. The Essential of Forensic Medicine & Toxicology. 34ed. 2020. Pp. 132-133.
- [4] Aggarwal A. *Exhumation*. Forensic Medicine & Toxicology. Avichal Publishing Company. Himachal Pradesh. 2nd ed. 2021. 114-115.
- [5] Jatti VB, Shobha, Satish KV, Kuppast NC, Kumar DR. Fatal stab injuries: a murder mystery revealed by exhumation. *Medico-Legal Update*. 2014;14(1):55-58. Doi: 10.5958/j.0974-1283.13.2.001.
- [6] Akhiwu WO, Nwafor CC. Exhumations: rarely done procedure but useful in many circumstances-a review of 47 cases in Nigeria. *Egypt J of Forensic Sci*. 2019;9:67:02-09. <https://doi.org/10.1186/s41935-019-0175-x>.

- [7] Selvaraja GR, Jih PK, Subramaniam K, Ibrahim NB. A case of suicide with multiple stab wounds. J Forensic Sci Med. 2019;5:164-67. <https://www.jfsonline.com/text.asp?2019/5/3/164/267149>.
- [8] Rani M, Kumar P, Kumar M, Rani Y. Exhumation and identification: A case report. J Indian Academy Forensic Med. 2012;34(4):361-63.

PARTICULARS OF CONTRIBUTORS:

1. Senior Resident, Department of Forensic Medicine and Toxicology, Kalpana Chawla Government Medical College and Hospital, Karnal and University of Health Sciences, Rohtak, Karnal, Haryana, India.
2. Associate Professor, Department of Forensic Medicine and Toxicology, Kalpana Chawla Government Medical College and Hospital, Karnal and University of Health Sciences, Rohtak, Karnal, Haryana, India.
3. Professor and Head, Department of Forensic Medicine and Toxicology, Kalpana Chawla Government Medical College and Hospital, Karnal and University of Health Sciences, Rohtak, Karnal, Haryana, India.
4. Professor, Department of Forensic Medicine and Toxicology, Pt. Bhagwat Dayal Sharma Postgraduate Institute of Medical Sciences, Rohtak and University of Health, Rohtak, Haryana, India.
5. Professor, Department of Forensic Medicine and Toxicology, Pt. Bhagwat Dayal Sharma Postgraduate Institute of Medical Sciences, Rohtak and University of Health, Rohtak, Haryana, India.

NAME, ADDRESS, E-MAIL ID OF THE CORRESPONDING AUTHOR:

Dr. Naveen Sharma,
Senior Resident, Department of Forensic Medicine and Toxicology, Kalpana Chawla Government Medical College and Hospital, Karnal and University of Health Sciences, Rohtak, Karnal, Haryana, India.
E-mail: dr.naveendhananiya@gmail.com

PLAGIARISM CHECKING METHODS: [\[Jain H et al.\]](#)

- Plagiarism X-checker: Dec 06, 2022
- Manual Googling: Dec 29, 2022
- iThenticate Software: Jan 31, 2023 (12%)

ETYMOLOGY: Author Origin**AUTHOR DECLARATION:**

- Financial or Other Competing Interests: None
- Was informed consent obtained from the subjects involved in the study? Yes
- For any images presented appropriate consent has been obtained from the subjects. Yes

Date of Submission: **Nov 21, 2022**Date of Peer Review: **Jan 04, 2023**Date of Acceptance: **Feb 01, 2023**Date of Publishing: **Apr 01, 2023**