



Ameliorative Potentials of *Vernonia amygdalina* on Acetaminophen-induced Acute Liver Injury in Mice

Hoang Le Son ^a, Ha Nguyen Anh Tu ^a and Tran Van Minh ^{a*}

^a Department of Applied Biochemistry, School of Biotechnology, International University-Vietnam National University Ho Chi Minh City, Vietnam.

Authors' contributions

This work was carried out in collaboration among all authors. All authors read and approved the final manuscript.

Article Information

DOI: 10.9734/AJB2T/2023/v9i2180

Open Peer Review History:

This journal follows the Advanced Open Peer Review policy. Identity of the Reviewers, Editor(s) and additional Reviewers, peer review comments, different versions of the manuscript, comments of the editors, etc are available here: <https://www.sdiarticle5.com/review-history/102145>

Original Research Article

Received: 27/04/2023

Accepted: 30/06/2023

Published: 05/07/2023

ABSTRACT

Aims: To investigate the ameliorative potentials of *Vernonia amygdalina* on acetaminophen-induced liver injury in mice.

Methodology: Acetaminophen-induced acute liver injury was conducted on Swiss-albino mice weighing 25 - 30 g. Group A was maintained as a negative control (healthy liver) while group B was assigned as a positive control (damaged liver). Group C, D and E were orally administered 100 mg/kg, 200 mg/kg and 400 mg/kg of dried *Vernonia amygdalina* leaf extract, respectively. Meanwhile, group F, G and H were orally administered 100 mg/kg, 200 mg/kg and 400 mg/kg of fresh *Vernonia amygdalina* leaf extract, respectively, for 21 days. All mice were subjected to the assessment of symptoms including the severity of liver injury, biochemical assay and histological features. Phytochemical screening was also performed as per standard test methods.

Results: Phytochemical screening revealed the presence of biological active compounds including alkaloids, flavonoids, saponins and terpenoids. Steroids were found in dried *Vernonia amygdalina*

*Corresponding author: E-mail: drminh.ptntd@yahoo.com;

leaf extract, but not in the fresh *Vernonia amygdalina* leaf extract. Compared to the pathological changes observed in the liver parenchyma, sinusoids and hepatocytes in the positive control group, lesions were determined to be less severe particularly in the group D receiving 200 mg/kg of dried *Vernonia amygdalina* leaf extract and group H receiving of 400 mg/kg of fresh *Vernonia amygdalina* leaf extract. This was in agreement with the biochemical assessment whose ALT and AST levels were significantly decreased into the normal range as compared to the negative and positive control groups. However, dose of 400 mg/kg dried *Vernonia amygdalina* leaf extract significantly elevated the serum ALT and AST.

Conclusion: *Vernonia amygdalina* has proven its ameliorative potentials on acetaminophen-induced liver injury in mice as determined by marked indicators on liver tissue and biochemical parameters including ALT and AST.

Keywords: *Vernonia amygdalina*; acute liver injury; acetaminophen; biochemical parameters; phytochemicals.

1. INTRODUCTION

According to the World Health Organisation, herbal sources have been primarily used as disease treatment methods where they are widely known to be the oldest form of healthcare. More than three quarters of the world population rely on traditional medicines, and herbal plants have long built the fundamentals for drug discovery and development where they often serve as lead compounds, producing over 50% of all modern clinical drugs in the pharmaceutical industry [1]. As at the present, the worsening situation of drug-resistant organisms has necessitated a journey looking for new therapeutic compounds, starting by outsourcing the natural herbal sources.

Vernonia amygdalina (*V. amygdalina*) belongs to genus *Vernonia* of the Asteraceae family. The plant, locally known as cây mật gấu (Vietnamese), is green with a characteristic odour and a bitter taste (Fig. 1). The taste is due

to anti-nutritional factors such as alkaloids, saponins, tannins and glycosides. The leaves are used for human consumption and washed before eating to eliminate the bitter flavour. In addition, using the leaves as vegetables is believed beneficial to health and well-being such as stimulating the digestive system or reducing fever [2]. Previous scientific investigations have pointed out the plant's complex active components that can be used pharmacologically. It is said to possess antimicrobial, antidiabetic, antimalarial, insecticidal, anti-inflammatory, anti-helminthic, hepatoprotective and anti-oxidative effects [3]. In ethno-medicine, the roots and leaves are used to treat fever, hiccups, kidney problems and stomach discomfort. Many West African countries such as Cameroon, Ghana and Nigeria use the stem and root as chewing sticks [4]. In Vietnam, the plant is recommended for mitigating conditions of diseases including diabetes type 2, gastrointestinal disorders and hyperlipidaemia.



Fig. 1. *Vernonia amygdalina*

High prevalence of liver injuries has shown no sign to stop over the years, especially when statistical data in 2017 showed that Vietnamese were among the tops in consuming alcohol annually together with availability of acetaminophen (N-acetyl-para-aminophenol) as an OTC drug. These heavy alcohol consumptions and uninformed usages of acetaminophen are risk factors leading to hepatic injuries; which, if left untreated or interfered, would lead to acute liver disease such as hepatitis, cirrhosis and liver cancer. Herbal medicine has been emerging as an appealing treatment alternative to ubiquitous synthesized drugs. Its benefits over the chemically synthetic medicine comprise of their mild toxicities and side effects to patients, together with a significant cost advantage in production. In Vietnamese ethno-medicine, there are plenty of herbs recommended for treatment of liver injuries. *V. amygdalina*, as at present, has been widely advised to use as a powerful ingredient in mitigating liver injuries due to its characteristic bitter taste. However, there still remain inconclusive scientific back-ups to the efficacy of this medicinal plant. Therefore, the main objective of this research is to screen for the potentials of *V. amygdalina* to be used as a medicinal herb on the basis of Vietnamese folk remedies, with regard to its in vivo therapeutic impacts on human's liver injuries and its biochemical properties. This would serve as a foundation for further research in optimization of extraction methods, development of *V. amygdalin*-based dietary supplements' formulations, proposing a possibility for industrial scale-up.

2. MATERIALS AND METHODS

2.1 Materials

2.1.1 Animals

The male Swiss-albino mice *Mus musculus* var., in good health conditions weighing of 25 - 30 g, were obtained from the Institute of Drug Quality Control - Ho Chi Minh City. They were housed in clean cages and had free access to standard diet and water *ad libitum*. During the experiment, mice were placed under a controlled climate and environmental condition with 12-hour of light and dark cycle. All the animals were acclimatized to laboratory conditions for a week prior to commencement of experiments. All experiments on mice were in accordance with the Guide for the Care and Use of Laboratory Animals (8th

edition) and Principles of laboratory animal care (NIH publication No. 85-23, revised 1985) [5].

2.1.2 Chemicals

N-acetyl-para-aminophenol (APAP) was obtained commercially under the trade name Efferalgan 500 mg effervescence. All chemicals used for the assays were purchased from Chemsol. All drugs and chemicals were stored in accordance with the most stringent regulations and freshly prepared with distilled water to the desired concentrations for experiment and treatment purposes.

2.2 Methods

2.2.1 Preparation of the plant extracts

Fresh *V. amygdalina* leaves were obtained from a local garden in Ho Chi Minh City. The plant was authenticated by The Institute of Tropical Biology, Vietnam and a voucher specimen of (No. AB Bio – 12 – 07 – 02) had been deposited in the herbarium of Applied Biochemistry Laboratory, Department of Applied Biochemistry, School of Biotechnology, International University Vietnam National University Ho Chi Minh City, Vietnam. They were placed in saline water for an hour and then washed thoroughly with running water to remove any possible contaminants. The leaves were divided into two equal portions, one was fresh and the other was dried leaves. The first half was left dry for two hours to remove water droplets, then macerated. The other half was dried in the oven at a temperature of 60°C for 24 hours. The dried leaves were then ground into fine powder and sieved in a cooking mesh to remove plums and later stored in a dessicator for later use. 25 g of fresh leaves was soaked in 330 mL of boiling water for 45 minutes. Meanwhile, 25 g of dried leave powder was placed in 250 mL of 100°C water for two hours. The extract was filtered through a cloth and Whatman No.1 filter paper to remove debris. The final filtrate was evaporated in vacuum by the rotary evaporator until forming a brownish residue. The residue, known as total extracts, was cold stored in the refrigerator at 4°C until the next use.

2.2.2 Preliminary phytochemical screening of the extracts

Phytochemical analysis of the extracts was performed for the detection of various constituents using standard techniques. 5 g of extracts from fresh leaves and dried leave

powder each was dissolved in 50 mL of distilled water and vortexed for the complete dissolution of all the components. The solution was left to stand at room temperature and filtered with Whatman No.1 filter paper. The filtrate was used for the phytochemical screening using the following tests [6]:

2.2.2.1 Tests for flavonoids

Ferric Chloride test: small quantities of various extracts were dissolved in 2 mL of ethanol; few drops of 10% ferric chloride were added. The formation of green blue coloration confirmed the presence of flavonoids.

Lead Acetate test: 1 mL of extracts was treated with few drops of 10% lead acetate solution. Formation of yellow colour precipitate indicated the presence of flavonoids.

2.2.2.2 Tests for alkaloids

Wagner's test: small quantities of various extracts were shaken with 2 mL of concentrated hydrochloric acid. A few drops of Wagner's reagent were added in the mixture. Formation of brown reddish precipitate indicated the presence of alkaloids.

Hager's test: small quantities of various extracts were shaken with 2 mL of concentrated hydrochloric acid. A few drops of Hager's reagent were added in the mixture. Formation of yellow precipitate indicated the presence of alkaloids.

2.2.2.3 Test for saponins

Frothing test: small quantities of various extracts were diluted with 4 mL of distilled water. The mixtures were shaken vigorously and then observed on standing for stable froth.

2.2.2.4 Tests for tannins

Small quantities of the various extracts were taken separately in 10 mL of distilled water, boiled and filtered. Tests for tannins were carried out with the following reagents.

Ferric Chloride test: to 2 mL of the filtrate, few drops of 5% ferric chloride were added. The formation of greenish black precipitate confirmed the presence of tannins.

Lead Acetate test: 2 mL of the filtrate was treated with few drops of 10% lead acetate solution.

Formation of precipitate indicated the presence of tannins.

2.2.2.5 Tests for phenolic compounds

Ferric Chloride test: 1 mL of different extracts was treated with 4 drops of 10% ferric chloride solution. Formation of deep blue or black colour indicated the presence of phenols.

2.2.2.6 Tests for anthraquinones

Borntrager's test: 1 mL of concentrated sulphuric acid was added to 1 mL of various extracts. The mixture was shaken gently and filtered. The filtrate was shaken with 1 mL of chloroform. The lower layer of chloroform was separated and shaken with half of its volume of 10% ammonium solution. The formation of rose pink at ammonia layer showed the presence of glycosides.

2.2.2.7 Tests for terpenoids

Salkowski's test: 5 mL of various extracts were mixed with 2 mL of chloroform followed by the careful addition of 3 mL concentrated sulphuric acid to form a layer. A layer of reddish brown coloration was formed at the interface and thus confirming a positive result for the presence of terpenoids.

2.2.2.8 Tests for steroids

Liebermann-Burchard's test: 2 mL of different extracts were dissolved in 2 mL of chloroform to which 10 drops of acetic acid and five drops of concentrated sulphuric acid were added and mixed. The change of red colour through blue to green indicates the presence of steroids.

2.3 Hydrogen Peroxide Scavenging Assay

The hydrogen peroxide scavenging assay was prepared by mixing 0.5 mL of plant extracts, 0.3 mL of phosphate buffer pH 7.4 followed by the addition of 0.3 mL of 40 mmol/L H₂O₂. The mixture was shaken gently and then left incubated for 10 min at room temperature. Absorbance of sample was measured against the blank at 230 nm using a spectrophotometer and Biotek Synergy HT 96-well plate [7]. The capacity to scavenge the hydrogen peroxide were calculated using the following equation:

% scavenging capacity (H_2O_2) = $(A_0 - A_1)/A_0 \times 100$

Where A_0 is the absorbance of the control, and A_1 the absorbance of the samples or standards. The assay was repeated three times, and the mean value of absorbance was recorded.

2.4 Mice Model

2.4.1 Induction of acute liver injury on mice model

The acetaminophen-induced acute liver injury (AILI) was performed on male Swiss albino mice weighing 25 - 30 g. Each mouse was weighed individually and labelled for appropriate APAP volume administration to the determined hepatotoxic APAP dose. Mice were divided into eight different groups with 6 mice per group ($n = 6$), of which AILI was done on seven groups while the other was kept as a negative control - healthy liver (group A). Since the LD_{50} was recommended in a range of 400 - 900 mg/kg BW [8], the dose of 300 mg/kg BW was chosen for oral administration via gavage tube of recommended gavage needle size for mice, for one week. When no deaths were observed, the dose was increased to 400 mg/kg BW, the lower bound of the recommended range for LD_{50} [9]. An effervescence containing 500 mg of APAP was dissolved in 25 mL of distilled water for a dose of 400 mg/kg. The APAP was administered daily during fasting period [10]. On week four, a mouse from each group was randomly picked and sacrificed to assess the hepatotoxicity via its liver observation [11].

2.4.2 Testing the effects of plant extract on mice model

Of the seven groups of inducing liver injury by APAP, six groups were chosen for testing the effects of plant extracts while the other was served as a positive control without receiving any plant extracts (group B). Weights were measured before feeding the plant extracts. Group C, D and E were orally fed with the dried leaf extract (DLE) at doses of 100, 200 and 400 mg/kg BW, respectively. Meanwhile, group F, G and H were orally fed with the fresh leaf extract (FLE) at doses of 100, 200 and 400 mg/kg BW, respectively. The procedure was done for 21 days.

2.5 Biochemical Tests of Liver Enzymes

At the end of week four, the liver's serum enzyme activities were measured, namely aspartate aminotransferase (AST) and alanine aminotransferase (ALT). Mice from each group (A to H) were picked and sacrificed. Its blood was sampled by cardiac puncture under light ether anaesthesia and stored individually in Li-Heparin tubes with according labels.

2.6 Liver Histological Examination

The liver structures were examined as part of assessing the effects of plant extracts on the AILI in male mice, directly. Comparative microscopic studies were done to examine if *V. amygdalina* leaf extracts were effective to restore the normal histo-architecture of the damaged liver. Moreover, it also made a comparison not only with doses but also between extracts of different starting materials, fresh leaves and dried leaf powder. This was done with the assistance of an expert at the Department of Histology and Pathology, School of Medicine, Vietnam National University Ho Chi Minh City. Upon obtaining the blood, the mice's livers were sectioned and the caudate lobe was used for histological studies. Caudate lobe was processed and stained with basic dye Heamatoxylin and Eosin at Tu Du hospital. All the images of liver anatomy were taken under the magnification of 10x and 40x to ensure the consistency of this study.

2.7 Statistical Analysis

Data were presented as mean \pm S.D. The significant differences were examined by 2-way ANOVA and post hoc test or two-tailed t test. Analyses were achieved by SPSS software and Microsoft Excel. All differences with a p value < 0.05 were considered statistically significant.

3. RESULTS

3.1 Preliminary Phytochemical Screening

The phytochemical tests revealed the presence of flavonoids, alkaloids, saponins and terpenoids in both extracts (fresh and dried leaves). On the contrary, anthraquinones, tannins and phenolic compounds were absent in both types of aqueous extracts. However, steroids were only found in DLE (Table 1).

Table 1. Phytochemistry of the aqueous extracts of *Vernonia amygdalina* from fresh and dried leaves

Phytochemical Screening		<i>Vernonia amygdalina</i> Extract	
Constituent	Phytochemical test	Fresh leaves	Dried leaves
Flavonoids	Lead acetate	+	+
	Ferric chloride	+	+
Alkaloids	Wagner's	+	+
	Hager's	+	+
Saponins	Frothing	+	+
Tannins	Lead acetate	-	-
	Ferric chloride	-	-
Phenolic compounds	Ferric chloride	-	-
Anthraquinones	Borntrager's	-	-
Terpenoids	Salkowski's	+	+
Steroids	Liebermann-Burchard's	-	+

“+” indicates positive test result; “-” indicates negative test result

3.2 Hydrogen Peroxide Scavenging Activity

The assay was performed with BHT as the reference standard to qualitatively compared the H₂O₂ scavenging activity, and then indirectly determined the antioxidant activities of each type of aqueous extract. The absorbance measured was converted to percentage of H₂O₂ scavenging (H%) as summarized in Fig. 2. FLE showed the highest scavenging activity with its H% was more than half, followed by the DLE while BHT was the lowest in H₂O₂ scavenging. Statistically, H₂O₂ scavenging activities of both BHT and DLE showed no significant difference ($p = 0.238$). In contrast, when comparing BHT and FLE, there is a significant difference ($p = 0.021$) that FLE even showed higher scavenging activity than the standard reference. In addition, both DLE and FLE indicated their antioxidant abilities at significantly different extent ($p = 0.031$).

3.3 Body Weight

Body weight was measured as gross observation, monitoring the mice's health over critical periods. In week 0, before the mice were brought for experiments, mice in all groups were in the range of 25 - 30 g. In week four, varies were observed in different groups (Table 2). Except group A without ALLI whose weights were increased after four weeks and even eight weeks, the other ALLI groups were witnessed a gradual decrease in body weight, even when provided with the same diet and drink. In week eight, only group G of 400 mg/kg FLE started to gain weight slightly, while group E of 400 mg/kg DLE had their weight remained unchanged. The other treated groups had their weight decreased at the rate that was significantly slower than before treatment ($p = 0.034$). Both of these groups were unable to reach the initial weights. Meanwhile, the untreated ALLI group B mice's weight was decreasing across the entire experimental period.

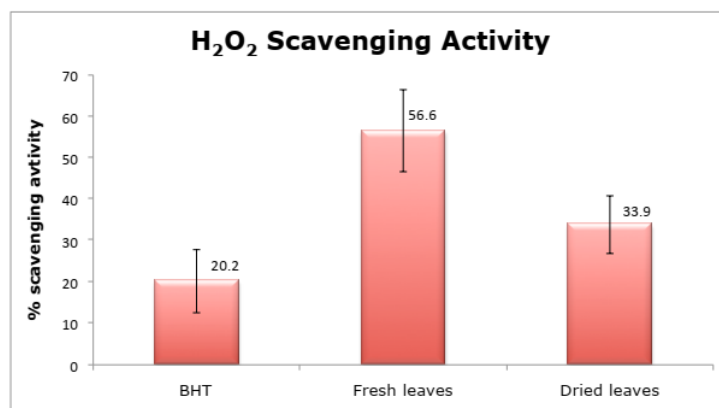


Fig. 2. Antioxidant ability via H₂O₂ scavenging activity of aqueous extracts from dried and fresh leaves with the standard BHT

Table 2. Changes in body weight of mice

Group of mice	Mouse's body weight (g)		
	Week 0	Week 4	Week 8
A	27.25 ± 0.96	28.75 ± 0.96	30.75 ± 1.50
B	27.75 ± 1.50	25.50 ± 1.29	22.25 ± 1.50
C	27.00 ± 1.63	23.50 ± 2.38	22.75 ± 1.17
D	25.50 ± 2.08	23.00 ± 1.83	22.75 ± 1.26
E	26.50 ± 1.29	23.00 ± 1.41	23.00 ± 0.82
F	26.75 ± 0.96	24.00 ± 1.41	23.50 ± 0.58
G	27.25 ± 0.96	23.75 ± 0.96	23.00 ± 0.82
H	27.75 ± 1.50	24.00 ± 1.41	24.25 ± 0.96

Group A: vehicle; Group B: APAP (400 mg/kg); Group C: APAP (400 mg/kg) + DLE (100 mg/kg); Group D: APAP (400 mg/kg) + DLE (200 mg/kg); Group E: APAP (400 mg/kg) + DLE (400 mg/kg); Group F: APAP (400 mg/kg) + FLE (100 mg/kg); Group G: APAP (400 mg/kg) + FLE (200 mg/kg); Group H: APAP (400 mg/kg) + FLE (400 mg/kg). Vehicle = Distilled water (negative control – healthy liver). APAP (400 mg/kg) = positive control - damaged liver. APAP = Acetaminophen. DLE = Dried leaf extract. FLE = Fresh leaf extract. Week 0 = before ALLI. Week 4 = before plant extract treatment. Week 8 = end of extract treatment and before sacrificing. Each value represents mean ± S.D. (n = 6)

3.4 Biochemical Tests of Liver Enzymes

As shown in Fig. 3A, the positive control group B displayed a significant increase in AST level by 1.5 fold to 55.8 ± 5.5 U/L as compared to the upper bound of the limit range ($p < 0.05$). This indicates that the liver was injured by APAP overdose; while the negative control group A showed a normal result within the accepted range. In plant extract-treated groups, the AST levels were in the normal range of less than 37 U/L, indicating that the liver was not badly injured. Amongst the groups receiving extract of dried and fresh *V. amygdalina* leaves, both group D and G of 200 mg/kg had the lowest AST level. Yet, AST level in group E of 400 mg/kg DLE was an abnormality, when its level was extraordinarily increased, reaching 182.5 ± 5.2 U/L by 5 times of the upper limit and by 3 times of the positive control group ($p < 0.05$).

As can be seen from Fig. 3B, the positive control group B has shown a remarkably significant increase in serum ALT level by 24 fold to 973.0 ± 7.8 U/L as compared to the upper bound of the limit range ($p < 0.05$). This indicates that the liver was extensively injured by APAP overdose; while the negative control group A showed a normal result within the accepted range. In treatment groups, the ALT levels were in the normal range of less than 40 U/L, indicating that the liver was not badly injured. Amongst the groups receiving plant extracts, both group D of 200 mg/kg of DLE

and group H of 400 mg/kg of FLE had the lowest ALT level. Yet, ALT levels in group E and G were not brought back to the normal range significantly, when its level was increased significantly ($p < 0.05$) even when treated with the plant extract, reaching 70.0 ± 8.6 , and 58.3 ± 8.3 U/L, respectively.

3.5 Liver Observation

On the observation of the gross appearance of livers of all groups, it was shown that there were some abnormal changes in texture and size compared to the vehicle group A. As can be seen from Fig. 4, group B showed a clearly deteriorated liver structure with nodular surface of scarred tissues and enlarged left lobe as indicated by the white arrow. Between group C, D and E receiving treatment of DLE, group D of 200 mg/kg showed the liver structure close to the vehicle group, of normal structure with minimal signs of a damaged liver. Group C had the most scarred surface while group E, despite receiving the highest dose of 400 mg/kg of DLE, still showed a rough surface. Between group F, G and H receiving treatment of FLE, group H of 400 mg/kg showed the structure that resembled the most to the vehicle group although the left lobe was relatively enlarged as shown by the white arrow as opposed to A. Meanwhile, group F had badly scarred and nodular surface of the liver structure with enlarged border indicated by white arrows.

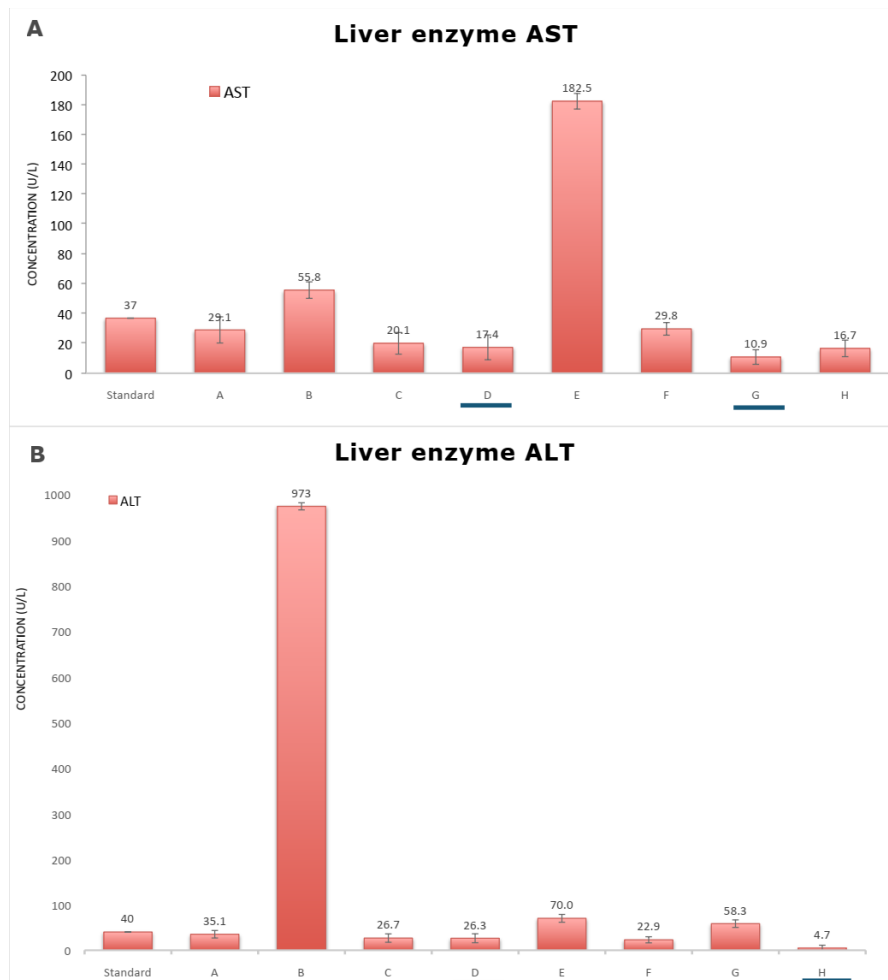


Fig. 3. (A): Concentrations of liver enzyme AST across different groups after eight weeks compared to the maximum allowance of 37 U/L. (B): Concentrations of liver enzyme ALT across different groups after eight weeks compared to the maximum allowance of 40 U/L

Group A: Vehicle; Group B: APAP (400 mg/kg); Group C: APAP (400 mg/kg) + DLE (100mg/kg); Group D: APAP (400 mg/kg) + DLE (200 mg/kg); Group E: APAP (400 mg/kg) + DLE (400mg/kg); Group F: APAP (400 mg/kg) + FLE (100 mg/kg); Group G: APAP (400mg/kg) + FLE (200 mg/kg); Group H: APAP (400 mg/kg) + FLE (400 mg/kg). Vehicle = Distilled water (negative control - healthy liver). APAP (400 mg/kg) = positive control - damaged liver. APAP = Acetaminophen. DLE = Dried leaf extract. FLE = Fresh leaf extract

3.6 Liver Histological Examination

Histological findings provided the liver's architecture across different testing groups. Group B was the APAP-challenged liver's histology as can be observed from Fig. 5. It clearly showed the signs of a damaged liver including hepatocyte ghosts, filtration of lymphoid cells as confirmed by the presence of red mass cells and visible nuclei. Meanwhile, group D and H showed some macro-vesicular steatosis on the hepatocytes, without inflammatory infiltrate. Whereas all groups C, E, F and G reflected severe macro-vesicular steatosis with remarkable characteristics in zone 1 and zone 2. Most of the hepatocytes in these groups had

characteristic foamy cytoplasmic appearance and changes in the nucleus. The nucleus was bright, big with visible nuclei. Some groups were even observed with degradation of macro-vesicular steatosis of hepatocytes with a small extent of inflammatory infiltrate of lymphoid cells in portal region. The centrilobular area were found to be degenerative with a mass of red cells, without visible cell membranes. The degenerative centrilobular area only occurs in zone 3, around the blood vessels in the centrilobule. The cell membrane was hard to observe, some degenerative cells form hepatocyte ghosts, but this characteristic was not observed in the group D and H. Meanwhile, the negative control group showed a normal liver

architecture of a healthy liver. In contrast, positive control group reflected all these three characterised distinctions of acute liver failure

including the hepatocyte's nucleus, infiltration of lymphoid cells and centrilobular necrosis at zone 3.

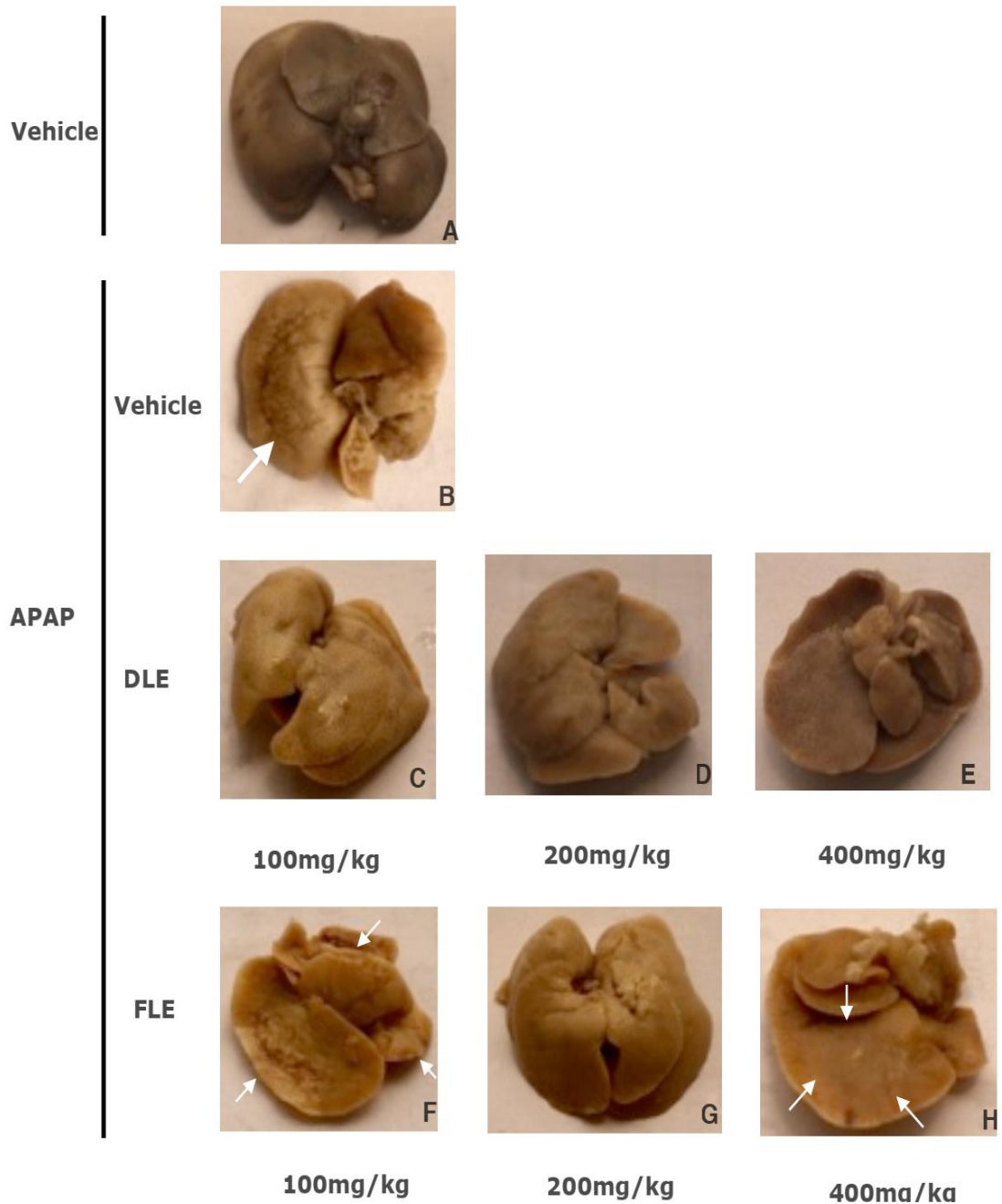


Fig. 4. Gross liver appearance from different groups

Group A: Vehicle; Group B: APAP (400 mg/kg); Group C: APAP (400 mg/kg) + DLE (100 mg/kg); Group D: APAP (400 mg/kg) + DLE (200 mg/kg); Group E: APAP (400 mg/kg) + DLE (400 mg/kg); Group F: APAP (400 mg/kg) + FLE (100 mg/kg); Group G: APAP (400 mg/kg) + FLE (200 mg/kg); Group H: APAP (400 mg/kg) + FLE (400 mg/kg). Vehicle = Distilled water (negative control - healthy liver). APAP (400 mg/kg) = positive control - damaged liver. APAP = Acetaminophen. DLE = Dried leaf extract. FLE = Fresh leaf extract

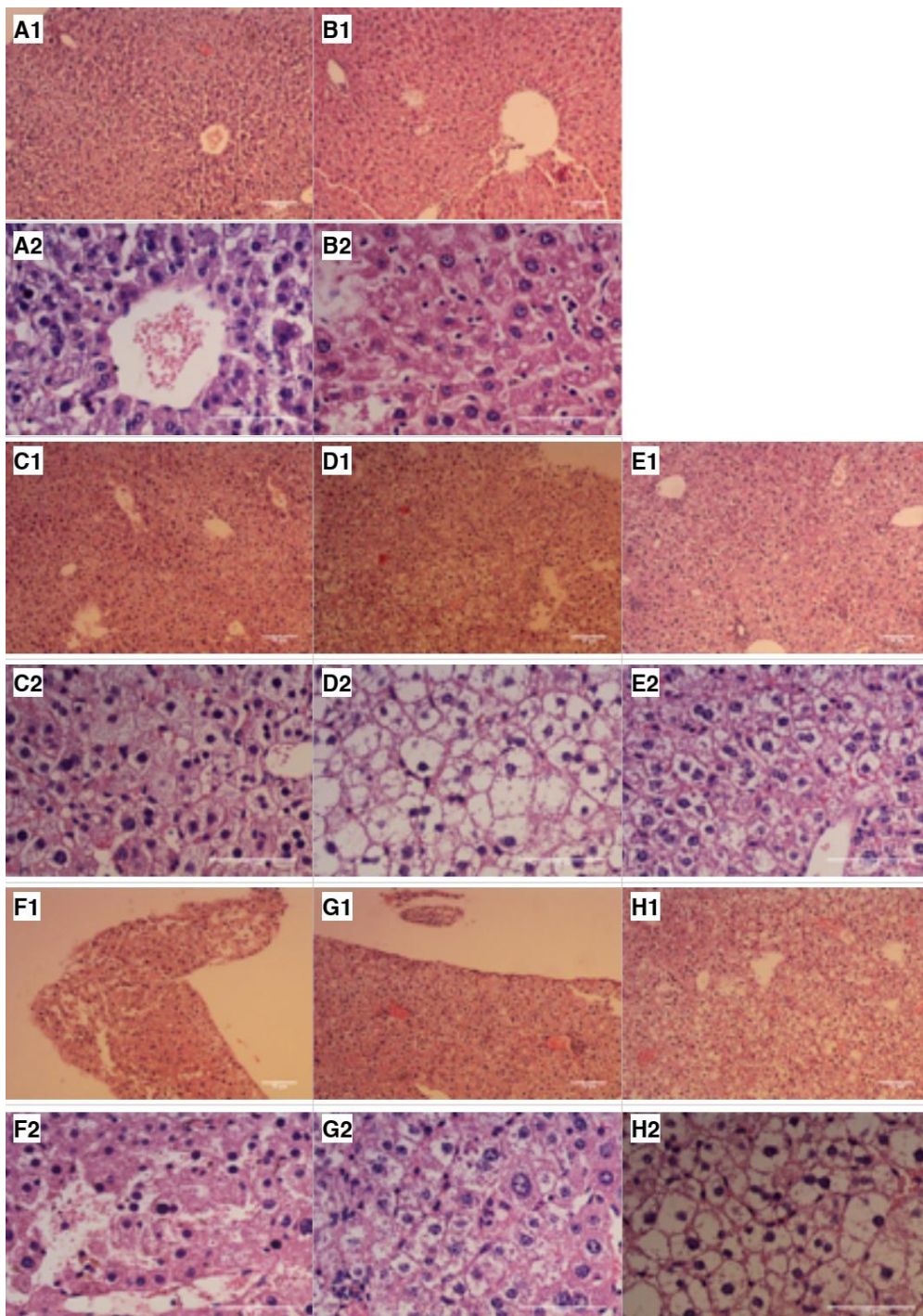


Fig. 5. Histology of H&E-stained liver from different groups

Group A: Vehicle; Group B: APAP (400 mg/kg); Group C: APAP (400 mg/kg) + DLE (100 mg/kg); Group D: APAP (400 mg/kg) + DLE (200 mg/kg); Group E: APAP (400 mg/kg) + DLE (400 mg/kg); Group F: APAP (400 mg/kg) + FLE (100 mg/kg); Group G: APAP (400 mg/kg) + FLE (200 mg/kg); Group H: APAP (400 mg/kg) + FLE (400 mg/kg). Vehicle = Distilled water (negative control - healthy liver). APAP (400mg/kg) = positive control - damaged liver. APAP = Acetaminophen. DLE = Dried leaf extract. FLE = Fresh leaf extract. A1-H1 = Microscopic image taken at 10x lens. A2-H2 = Microscopic image taken at 40x lens

4. DISCUSSION

The preliminary phytochemical screening tests may be useful in the detection of the bioactive principles and subsequently may lead to the drug discovery and development. Furthermore, these tests facilitate their quantitative estimation and qualitative separation of pharmacologically active chemical compounds. Previous studies report that washed *V. amygdalina* leaves better liberate the phytochemical compounds [12]. This is reflective that aqueous extracts have several contents of phytochemical compounds. Alkaloids, found in both types of extracts, were not heat labile as the extracts were done at 100°C. However, water is not an adequate solvent for extracting phenolic compounds, tannins and anthraquinones. On the other hand, DLE has steroids while FLE lacks, which was in agreement with previous reports [13-15].

Total phenolics are well known to constitute one of the major groups of compounds acting as primary antioxidants or free radical terminators. Meanwhile, flavonoids are the most widespread group of natural compounds and probably the most important natural phenolics as a result of their health-promoting benefits. H₂O₂ is highly important because of its ability to penetrate into biological membranes. H₂O₂ itself is not very reactive, but it can sometimes be toxic to cell because it may give rise to hydroxyl radicals in the cells [16]. Scavenging of H₂O₂ by extracts may be attributed to their phenolics, which can donate electrons to H₂O₂, thus neutralising it to water [17]. The results show that all the extracts had potent H₂O₂ scavenging activity and reducing capacity which may be due to the antioxidant compounds. Moreover, phenolic compounds and flavonoids have been reported to be associated with antioxidative action in biological systems, acting as scavengers of singlet oxygen and free radicals [18]. These findings indicated that FLE possesses higher antioxidant capacity than DLE significantly at the significant level of 0.05. This is similar to previous reports that *V. amygdalina* can be served as an antioxidant source [4].

V. amygdalina is widely known to possess various therapeutic applications in ethno-medicine, and scientific advancement through technology has provided substantial evidence to support most of its medicinal claims. The present *in vivo* study has further demonstrated the hepato-protective potentials of this plant. In this study, hepatocellular damage induced by

acetaminophen intoxication in mice was established based on significant elevations in serum ALT and AST concentrations as found by previous research [19]. The more specific cytosolic ALT, found in high concentration in the liver, and AST, which is localised in the cytosol and mitochondria, are released into the circulation in the early phase of liver injury. Injuries of liver cells (hepatocytes) allowing for escape of these enzymes into the bloodstream raises their levels in the blood. Normal levels are in the range of less than 37 units per litre for AST and below 40 units per litre for ALT. Mild elevations are generally considered to be 2-3 times higher than the normal range. In some conditions, these enzymes can be severely elevated, in the 1000s range [20]. In the present liver function tests, there were significant changes, back to the normal range, in the serum level of ALT and AST in most animal groups treated with different doses of the DLE and FLE in comparison to the positive control. Such significant change of these enzymes between the positive control and treated group of animals after four weeks of administration indicates that the aqueous leaf extract imposes a therapeutic effect on the injured livers. However, a significant increase in level of AST and ALT was observed in male mice treated with 400 mg/kg of DLE (group E), even much higher than that of positive control group while this was not seen in the group with the same dose of FLE (group H). Previous studies confirm that liver toxicity has been reported following the use of phyto-therapeutic products [21]. The difference in the phytochemical constituents can be attributed to this biochemical change abnormality. In this study, steroids were found in DLE, but absent in FLE. It is noteworthy to know that traditional medications that are contaminated with steroids raise a lot of concerns especially if taken over a long-term period [22]. The body's immune response is weakened and the ability to fight infection is reduced, increasing blood pressure, bruising, acne, swollen hand, sore or weak muscles. At a dose as high as 400 mg/kg, the extract was likely contained a higher amount of steroids and the four-week long daily administration of steroids led to the liver's inability in detoxifying, resulting in liver toxicity. However, there is no known mechanism involved affirming the correlation between administering steroid-containing substance and liver toxicity, yet. The body weight changes across the experimental period with three critical time periods were recorded and shown to be in accordance with biochemical changes. The AILI

group presented a steady decline in weight, while in treated groups, the weight decrease was ceased and some were slightly increased upon the plant extract treatment, except for the group administering 400 mg/kg DLE. The body weight is reflective of the health condition of mice in each group. In addition, treated groups of animals showed changes in the gross structures of liver as compared to the AILI control. This reaffirms that the aqueous leaf extracts of *V. amygdalina* did impose a hepato-protective effect even when mice were continuously administered APAP while being treated. Moreover, the therapeutic effect of *V. amygdalina* leaf extract can be attributed to its antioxidant capacity which is believed to be role of flavonoids present in both DLE and FLE.

Histopathological examinations provide information to strengthen the findings on biochemical and liver's gross appearance parameters. The liver is functionally divided into three zones with zone 1 being closest to the hepatic portal vein and zone 3 being the furthest away, receiving the least oxygen amount. The histological findings, in addition, confirmed the effectiveness of treating 400 mg/kg FLE or 200 mg/kg DLE when the centrilobular necrosis in zone 3 was not seen and a significantly small quantity of lymphoids cells were infiltrated. This indicates the ability of *V. amygdalina* leaf extracts in mitigating the acute liver failure signs in the treatment group as compared to that of positive control group with visible centrilobular necrosis. However, in some cross-sections pertaining to these two groups, lymphoid cell infiltrations were observed in the liver parenchyma, and this event can be regarded as the reaction of the liver to *V. amygdalina* leaves as previously reported that the liver might be likely to react to foreign substances which are not synthesized in the body. However, this is not considered to be an adverse effect on the liver [23]. In this study, there are some differences in characteristics from previous histological studies of AILI including macrovesicular steatosis occurring mostly in zone 1 and 2. This can be due to the fact that these cells are not yet regenerated by healthy hepatocytes or the existence of macrovesicular steatosis remains. Moreover, when challenged with APAP, damaged liver fails to function normally resulting in metabolic disorder of carbohydrates and glucose, which supply 70% of the total energy daily [24]. In order to supply energy for body performance substantially, the body has to outsource the lipid storage. As a result of lipid metabolism coupled with liver

detoxifying malfunction, increasing the triglyceride production, thereby worsening the macro-vesicular steatosis. It is also noticeable that, at dose as high as 400 mg/kg of DLE, it might induce focal mononuclear lymphocytic infiltration in microscopic structures of the liver. This change was transferable to the significantly increased AST and ALT level.

5. CONCLUSION

It is conclusive that doses of 200 mg/kg for DLE and 400 mg/kg for FLE have shown to impose most therapeutic effects on acetaminophen-induced acute liver injury in mice. Since the FLE contains no steroids it can be beneficial for further investigation and DLE needs to be taken into consideration, but at a lower dose than the DLE. Another improvement can be made is to study the toxicity limit of the plant extract on mice with larger population.

ETHICAL APPROVAL

Animal Ethic committee approval has been collected and preserved by the author(s).

ACKNOWLEDGEMENT

The authors gratefully acknowledge all the support of International University (Vietnam National University Ho Chi Minh City) and the Center of Analytical Services and Experimentation HCMC.

COMPETING INTERESTS

Authors have declared that no competing interests exist.

REFERENCES

1. Farnsworth NR. The role of ethnopharmacology in drug development. Ciba Found Symp. 1990;154:2-11; discussion 11-21. DOI: 10.1002/9780470514009.ch2. PMID: 2086037.
2. Atangwho IJ, Ebong PE, Eyong EU, Williams IO, Eteng MU, Egbung GE. Comparative chemical composition of leaves of some antidiabetic medicinal plants: *Azadirachta indica*, *Vernonia amygdalina* and *Gongronema latifolium*. African Journal of Biotechnology. 2009;8(18):4685-4689. Available:<http://www.academicjournals.org/AJB>.

3. Kelly O, Ehigbai IO, Nkeiruka E, Ogechukwu A, Omorede A, Ehimwenma SO. Comparative Antioxidant Activities of Extracts of *Vernonia amygdalina* and *Ocimum gratissimum* Leaves. Journal of Agricultural Science. 2014;6(1).
4. Imaga NOA, Bamigbetan DO. In vivo biochemical assessment of aqueous extracts of *Vernonia amygdalina* (Bitter leaf). International Journal of Nutrition and Metabolism. 2013;5(2):22-27. Available:<http://www.academicjournals.org/IJNAM> DOI: 10.5897/IJNAM12.0001
5. National Academies Press. Guide for the Care and Use of Laboratory Animals, 8th edition. 2010:1–246.
6. Harborne JB. Phytochemical Methods. A Guide to Modern Techniques of Plant Analysis; 1973.
7. Al-Amiery AA, Al-Majedy YK, Kadhum AA, Mohamad AB. Hydrogen Peroxide Scavenging Activity of Novel Coumarins Synthesized Using Different Approaches. PLoS One. 2015 Jul 6;10(7):e0132175. DOI: 10.1371/journal.pone.0132175. PMID: 26147722; PMCID: PMC4492988.
8. Salmi M, Adams D, Jalkanen S. Cell adhesion and migration. IV. Lymphocyte trafficking in the intestine and liver. Am J Physiol. 1998;274(1):G1-6. DOI: 10.1152/ajpgi.1998.274.1.G1. PMID: 9458766.
9. Larson AM. Acetaminophen hepatotoxicity. Clin Liver Dis. 2007 Aug;11(3):525-48, vi. DOI: 10.1016/j.cld.2007.06.006. PMID: 17723918
10. Kim SN, Seo JY, Jung DW, Lee MY, Jung YS, Kim YC. Induction of hepatic CYP2E1 by a subtoxic dose of acetaminophen in rats: increase in dichloromethane metabolism and carboxyhemoglobin elevation. Drug Metab Dispos. 2007;35(10):1754-8. DOI: 10.1124/dmd.107.015545. Epub 2007 Jul 9. PMID: 17620348.
11. Mossanen JC, Tacke F. Acetaminophen-induced acute liver injury in mice. Lab Anim. 2015 Apr;49(1 Suppl):30-6. DOI: 10.1177/0023677215570992. PMID: 25835736
12. Sani AA, Alemika ET, Abdurraheem RO, Abdulkareem SS, Abdurraheem RB, Ilyas M. A Study Review of Documented Phytochemistry of *Vernonia amygdalina* (Family Asteraceae) as the Basis for Pharmacologic Activity of Plant Extract. Journal of Natural Sciences Research. 2012;2(7).
13. Bhandary S, Kumari S, Bhat V, Sherly S, Bekal M. Preliminary phytochemical screening of various extracts of *Punica granatum* peel, whole fruit and seeds. Nitte University Journal of Health Science. 2012;2. DOI:10.1055/s-0040-1703609
14. Alabri T, AL.Musalami P, Hossain M, Weli A, Al-Riyami Q. Comparative study of phytochemical screening, antioxidant and antimicrobial capacities of fresh and dry leaves crude plant extracts of *Datura metel* L. Journal of King Saud University - Science. 2014;26: 237-243.
15. Usunomena U, Okolie N. Phytochemical analysis and proximate composition of *Vernonia amygdalina*. International Journal of Scientific World. 2016;4-11. DOI: 10.14419/ijsw.v4i1.5845
16. Keser S, Celik S, Turkoglu S. Total phenolic contents and free-radical scavenging activities of grape (*Vitis vinifera* L.) and grape products. Int J Food Sci Nutr. 2013;64(2):210-6. DOI: 10.3109/09637486.2012.728199. Epub 2012 Oct 2. PMID: 23025419.
17. Pisoschi A, Negulescu G. Methods for Total Antioxidant Activity Determination: A Review. Biochemistry & Analytical Biochemistry. 2012 01. Available: 10.4172/2161-1009.1000106.
18. Oriakhi K, Erharuyi O, Oikeh E, Engel N, Falodun A. Free radical scavenging and cytotoxic effects of methanol extract of *Theobroma cacao* L. (Sterculiaceae) seed 1 2 3 4 2. West African Journal of Pharmacy. 2015;26:1-9.
19. Yusmazura Z, Nurhazirah ZA, Nik FNH, Hussin M. Phytochemicals and acute oral toxicity studies of the aqueous extract of *Vernonia amygdalina* from state of Malaysia. Journal of Medicinal Plants Studies. 2016;4(3).
20. Kanbur M, Eraslan G, Beyaz L, Silici S, Liman BC, Altinordulu S, et al. The effects of royal jelly on liver damage induced by paracetamol in mice. Exp Toxicol Pathol. 2009;61(2):123-32. DOI: 10.1016/j.etp.2008.06.003. Epub 2008 Aug 6. PMID: 18693095.
21. Nawwar MAM, Barakat HH, Buddrust J, Linscheidt M. Alkaloidal, lignan and

- phenolic constituents of Ephedra alata. Phyto-chemistry. 1985;24: 878–879.
22. Ismail Z, Mohamed R, Mohd HMH, Wan SK. Usage of traditional medicines among elderly and the prevalence of prednisolone contamination. Malays J Med Sci. 2005; 12(2):50-5.
PMID: 22605958;
PMCID: PMC3349401.
23. Percy DH, Barthold SW. Pathology of laboratory rodents/ rabbit, 2nd ed. Iowa State Press; 2001.
24. Schneeweiss B, Pammer J, Ratheiser K, Schneider B, Madl C, Kramer L, et al. Energy metabolism in acute hepatic failure. Gastroenterology. 1993;105(5): 1515-21.
DOI: 10.1016/0016-5085(93)90159-a.
PMID: 8224656

© 2023 Son et al.; This is an Open Access article distributed under the terms of the Creative Commons Attribution License (<http://creativecommons.org/licenses/by/4.0>), which permits unrestricted use, distribution, and reproduction in any medium, provided the original work is properly cited.

Peer-review history:

The peer review history for this paper can be accessed here:
<https://www.sdiarticle5.com/review-history/102145>