



## Hepatic Hydatidosis Management

**Ritika Sharma<sup>a\*#</sup>, Vanee Meghrajani<sup>a#</sup>, Shricha Bhutda<sup>a#</sup>, Sakshi Bhutada<sup>a#</sup>  
and Meenakshi Yeola<sup>b≡</sup>**

<sup>a</sup> *Jawaharlal Nehru Medical College, Datta Meghe Institute of Medical Sciences, Wardha, India.*

<sup>b</sup> *Department of Surgery, Jawaharlal Nehru Medical College, Datta Meghe Institute of Medical Sciences, Wardha, India.*

### **Authors' contributions**

*This work was carried out in collaboration among all authors. All authors read and approved the final manuscript.*

### **Article Information**

DOI: 10.9734/JPRI/2021/v33i60B34875

### **Open Peer Review History:**

This journal follows the Advanced Open Peer Review policy. Identity of the Reviewers, Editor(s) and additional Reviewers, peer review comments, different versions of the manuscript, comments of the editors, etc are available here: <https://www.sdiarticle5.com/review-history/81318>

**Review Article**

**Received 20 October 2021**  
**Accepted 23 December 2021**  
**Published 25 December 2021**

## **ABSTRACT**

Hydatid cyst disease is a tapeworm infection caused by the larvae of echinococcus granulosus, spread through contaminated water and food. Hepatic hydatid cysts have different clinical manifestations. The investigations include X-rays, ultrasonography, computerized tomography, magnetic resonance, and ERCP used to detect deep lesions in all the organs and extent and status of avascular fluid-filled cysts. An antibody test is done to confirm x-ray findings. The drug Albendazole influences medical treatment. Albendazole chemotherapy proved to be an effective therapy preferred in the medical care of cystic echinococcosis. Radical hepatic hydatid cysts surgery refers to peri-cystectomy, and Conservative surgery removes the cystic contents, sterilizes the cavity, and resects the part of the cyst. Laparoscopic surgery offers the advantages of a short hospital stay, less wound infection incidence rate, and minimal post-operative pain. Percutaneous aspiration injection re-aspiration is suitable in patients who are not fit for surgery or are not ready for the surgery and have multiple cysts in the liver. The conclusion of this review article is compared to open surgery for hepatic hydatid cysts; we have shown that laparoscopic surgery can be performed safely even with multiple cysts, large cysts, and bile duct cysts.

**Keywords:** *Albendazole; hepatic; hydatid cyst disease; pericystectomy; PAIR; liver resection; sporicidal agents.*

<sup>#</sup>MBBS Students;

<sup>≡</sup>Professor and Head;

<sup>\*</sup>Corresponding author: E-mail: ritika.sharma9098@gmail.com;

## 1. INTRODUCTION

Hydatid disease is a tapeworm disease caused by the larvae of *Echinococcus granulosus*, which is life-threatening. The incidence of the disease is closely related to specific geographic regions of the world. Hepatic hydatid cysts have different clinical manifestations, and many people are infected with cystic hydatid disease [1].

Hydatidosis is very rare in European countries outside the endemic area of the Mediterranean [2]. *Echinococcus granulosus* exists almost everywhere globally and is most common in countries where sheep and cattle are raised. (<1 case / 1 million) in the United States. No sexual orientation. In 50% -70% of echinococcosis cases, the liver is affected.

*E. granulosus* is a hermaphroditic flatworm. There are three stages of development. The cyst usually consists of three parts: the pericyst, which is formed by the host's inflammatory tissue, the external capsule, and the internal capsule, which produces brood capsules with scolices [3].

In some cases, asymptomatic hydatid cysts are diagnosed when they become symptomatic. The cysts gradually grow (1-2cm/year), and unless

the brain is affected, it is rarely diagnosed during childhood or adolescence. The incubation period is months to years and even decades.

Investigations for diagnostic purposes are plain x-ray abdomen, chest showing Calcification, ultrasonography, computerized tomography, magnetic resonance imaging, Casoni test, endoscopic retrograde cholangiography, liver function test, a routine hematological test showing elevated total leukocyte count, and eosinophilia.

Medical treatment consists of Albendazole or Praziquantel. The management of hydatid cysts of the liver usually involves surgery as the main component of treatment. The surgical approach aims to drain the contents inside the cyst and the germ layer surrounding the cyst while taking extreme precautions to prevent the contents of the cyst from spilling out [4].

The main aims of hydatid surgery are

- complete removal of infectious components of the cyst.
- avoid the spillage of the cyst's contents during the surgery.
- residual compartment treatment.
- minimize operational risk.

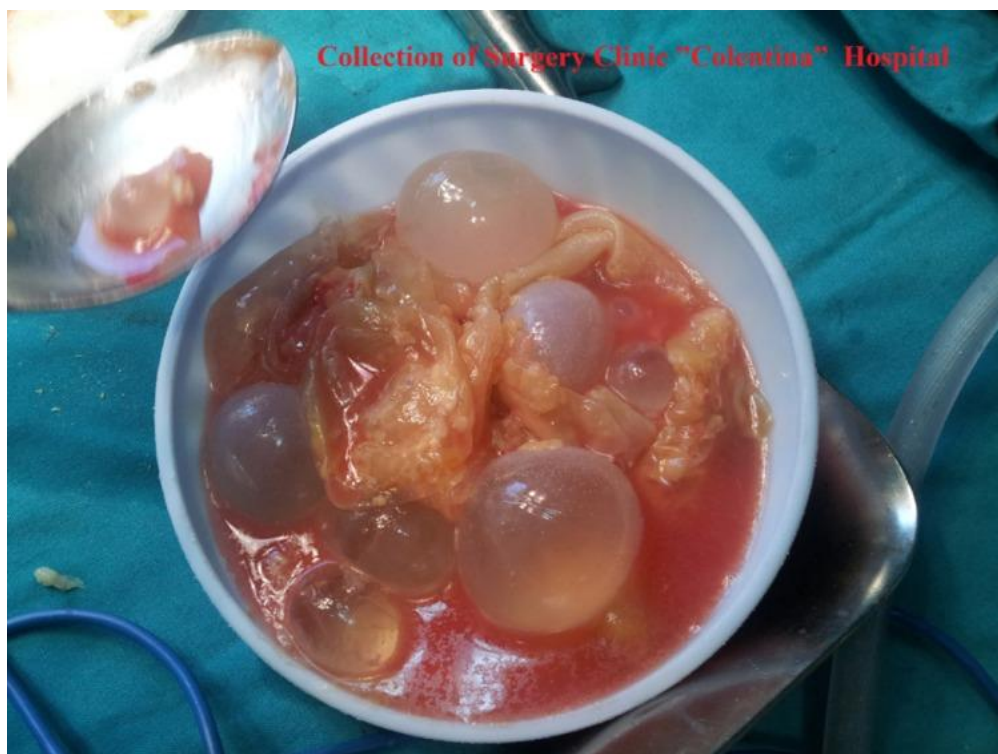

Fig. 1. Collection of surgery clinic "Colentina" hospital

## 2. DIAGNOSIS AND MANAGEMENT

### 2.1 Investigations

The existence of cysts in a patient with a history of contact with sheep and dogs in E. granulosus-endemic areas raises the possibility of cystic echinococcosis. On the other hand, Hydatid cysts must be distinguished from benign cysts, abscesses, cysts caused by pituitary TB, and benign or malignant tumors. The existence of cysts in a patient with a history of contact with sheep and dogs in E. granulosus-endemic areas raises the possibility of cystic echinococcosis. On the other hand, Hydatid cysts must be distinguished from benign cysts, abscesses, cysts caused by pituitary TB, and benign or malignant tumors.

Confirmation of the non-invasive diagnosis can also be done using a combination of immunologic diagnostic techniques and radiographic imaging. X-rays can detect hepatic hydatid cysts.

Magnetic resonance imaging, computed tomography, and ultrasound help detect deep lesions in all organs and determine the extent and status of avascular fluid-filled cysts.

Due to its availability and use in detecting the number of cysts, their location, size, and viability, abdominal ultrasound is the most commonly utilized imaging diagnostic tool for echinococcosis.

Type CL- unicellular cystic lesion with uniform reflectance is one of the classification systems (but ultrasound did not detect any pathological findings).

Type CE-1 single mass cyst with equal echogenicity and pathological findings including visible signs of cyst wall;

Type CE-2, multifocal, multisensory cyst;

Type CE-3, multi-layer membrane from the cyst wall visible as a floating membrane or “water lily sign”;

Type CE-4 heterogeneous hypoechoic degeneration content, no cysts;

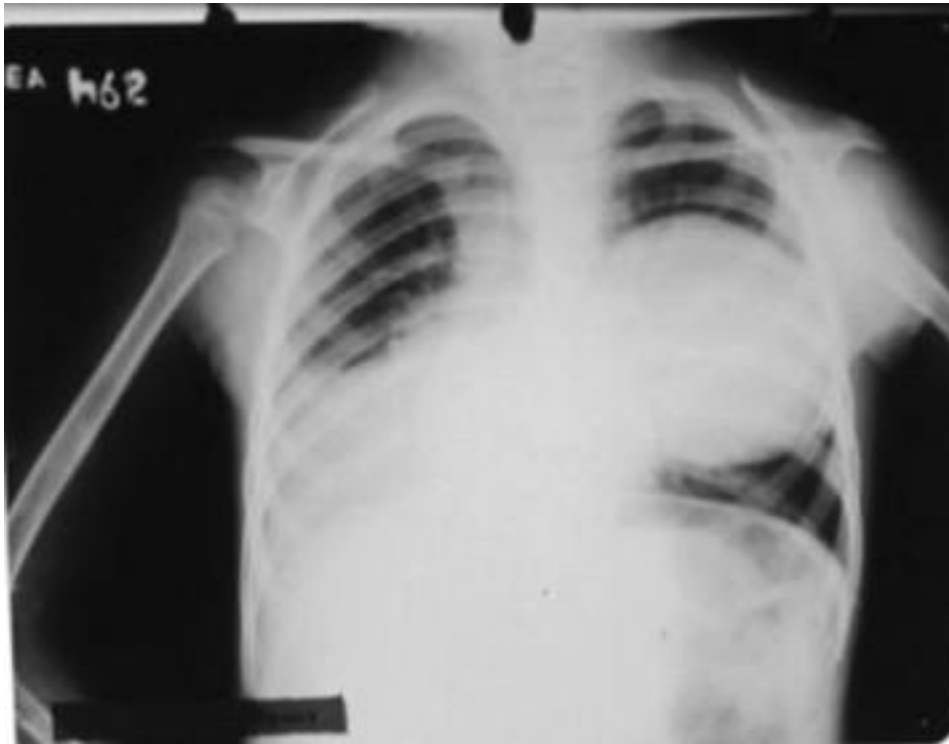Type CE-5 the cyst has a thick, arcuate outer membrane of calcifications, producing a conical shadow.

An antibody test is used to confirm X-ray findings, although some patients with cysticercosis lack immune response.

Liver cysts are susceptible to show immune response as compared to hepatic cysts. In any case, site, the sensitivity of serological tests is inversely proportional to the extent of arrangement of parasitic antigens in the cyst; For example, healthy, intact cysts may produce significantly little response, while ruptured or leaking cysts gives a good response.

**Table 1. WHO-IWGE classification of the hydatid cyst**

Stage	Echographic aspect according to WHO-IWGE Classification
CL	Anechogenic uniloculated cyst with no echoes on internal sepsis
CE1	Anechogenic cyst with fine echoes inside, representing the hydatid sand-active cyst
CE2	Cyst with multiple septums at the interior, giving it a multivesicular aspect or honeycomb aspect with a uniloculated primary cyst – active cyst
CE3	Uniloculated cyst with decollated proligere membrane (waterlily sign) (CE3a) or daughter vesicles associating hypo/hyperechogenic images (CE3b)- cyst in transition phase
CE4	Cyst with mixed content, hypo/hyperechogenic , without daughter vesicles – “wool clew” aspect – cyst in the degenerative phase
CE5	Cyst with partial or totally calcified wall- inactive cyst



**Fig. 2. Chest x-ray of a 6-year old girl showing hydatid cyst in the left lung in endemic areas [4]**

The indirect coagulation test is sensitive but is replaced by an enzyme immunoassay. Specific confirmation of sensitivity is obtained by presenting echinococcal-specific antigens by immunoblot tests. <24% of patients are detected with Eosinophilia.

In seronegative patients, the most likely diagnosis is confirmed by demonstrating pigments or cyst membranes in the fluid taken from percutaneous aspiration of the cyst. Ultrasonographic guidance on punctures, deworming blankets, and predictive abilities needed to treat an allergic reaction minimizes risk.

Pigment preservation can sometimes be found in sputum or bronchoalveolar lavage; hooks are easier to identify thanks to acid-fast stains [4].

### 3. MEDICAL TREATMENT

The use of benzopamidazole (albendazole) and mebendazole are studied:

The World Health Organization (WHO) compares two periods in Europe to compare albendazole or mebendazole drugs. All medications have had similar efficiency, but the mebendazole needed

greater capacity. In RCT, which was carried out in Franchi et al. to compare the effectiveness of albendazole or mebendazole, treatment with albendazole showed better results than mebendazole [4].

Albendazole Chemotherapy proved to be an effective therapy preferred in the medical care of Cystic Echinococcosis.

Albendazole with praziquantel treated in combination has a high scolicial and anti-cyst activity and deformation has increased and may cause treatment or improvement over albendazole alone [5].

## 4. SURGICAL TREATMENT

### 4.1 Radical Vs Conservative Surgical Treatment

Radical hepatic hydatid surgery refers to pericystectomy, while conservative surgery consists of removing cystic contents and sterilizing the cavity, and resectioning part of the cyst.

Several retrospective non-comparative studies conclude that radical surgery is the safest and widely accepted.

In a study of 240 patients, Aydin et al. found that individuals who underwent conservative surgery had considerably higher morbidity and recurrence.

The aggressive and cautious surgeries were evaluated in single randomized research with 34 individuals. The researchers concluded that conservative surgery had a higher probability of early recurrence and intracystic complications ( $P = 0.012$ ) than radical surgery [3].

A policy of radical surgery can be followed as far as possible with acceptable morbidity and near-zero mortality. However, radical surgery has been judiciously applied and still has a vital role in conservative surgery [2].

## 5. LAPAROSCOPIC APPROACH FOR HYDATID DISEASE

The use of laparoscopy to treat hepatic hydatid cysts was first documented in 1992 [3]. Eight series have been published, including five or more patients, most of which use laparoscopic cystectomy technique [5].

Describes a particular trocar system and operating techniques. A total of 76 patients underwent surgery using this technique.

In 83% of patients, hydatid cysts were eliminated by PHS alone. A left lobectomy was performed in

13.7% of the patients because the cyst was so large that it occupied almost the whole left liver lobe. The residual cavity is managed by otoplasty. The mean follow-up time was five years, during which there was no recurrence seen [6].

Compared to open surgery, laparoscopic surgery offers the advantages of a short hospital stay, less wound infection incidence rate, and minimal postoperative pain [7]. The disadvantage is that it is challenging to locate the capsule in certain positions, the risk of overflowing the contents of the capsule increases, and it is difficult to aspirate the capsule.

Laparoscopic surgery technology has been successfully applied in managing liver hydatid cysts. Although the use of these procedures is limited to highly endemic areas and units of specific interest, laparoscopic surgery is now a management option for treating hepatic hydatidosis [5].

## 6. DRUG TREATMENT WITH SURGERY

Akanpatients'ed Forty-nine patients non-randomized trial. Albendazole was administered pre-operatively. Albendazole had a significant success rate in treating patients with hydatid cysts.




Fig. 3. Google images

Albendazole was given one month before surgery and two months post-surgery to 27 patients. In both scenarios, the pharmacological treatment was tested for abnormal hepatic enzymes. Twenty-two patients were remaining; recurrence was not seen during the average monitoring period [6] of 28 months.

Combination treatment with Albendazole + surgery is less risky to resort only to surgery.

### 6.1 Percutaneous Aspiration Injection Reaspiration plus Albendazole for Hepatic Hydatid Cysts

PAIR is suitable for patients who are not fit for surgery, are not ready for surgery, and have many cysts in the liver, spleen, kidneys, and bones [4].

All patients going for percutaneous drainage were given albendazole orally, usually once a day before and post drainage. Perform percutaneous drainage under ultrasound guidance to closely monitor complications such as allergic reactions, laryngeal edema, and bronchospasm.

The procedure usually requires three steps: The cyst's puncture and needle aspiration, installation and long-lasting cervical spine solution for about 25-35 minutes, and re-aspiration and final flushing of the cyst. Of the 770 patients, 73 (10%) received needle decompression and catheter drainage for type 3 and 4 cysts and left the catheter in place for 1 to 11 days after drainage. Immediately after aspiration or catheter drainage, perform cytological, histopathological, and parasitological examinations of the cyst fluid or surgical tissue sample to confirm the diagnosis and evaluate the success rate of the drainage. Motility and staining pattern with an optical microscope is observed, and neutral red staining is done (to prove active parasites) and methylene blue (to prove inactive organisms) to assess the viability of the protocranial segments [8].

In the reviewed study, the following stated criteria are used for the success of PAIR treatment

- (A) Under ultrasound, the internal cyst is separated from the cyst in the polycystic cyst, and the secondary vesicle ruptures. The size of the cyst gradually decreases until it disappears. The size does not increase during the follow-up period. Level of echogenic material, or disappear entirely

and have an uneven echo pattern (pseudotumor formation);

- (B) On CT, the cyst density increases;
- (C) In serological and parasitological examinations, the serological titer is Negative with no complication.

The patient was observed for approximately five months. Continuous ultrasound and CT were performed to evaluate the ultrasound mode, the size of the liver cyst cavity, which was currently present. ELISA detects serum IgG and IgM antibodies. Serological titer >1:150 is considered positive.

Surgical intervention includes Conservative and Radical methods. Conservative methods include tube drainage, marsupialization, capping (by suture, Opposite surfaces are brought closer together to close the cyst cavity surgically), open-top, simple partial cystectomy. Radical surgery includes lobectomy, complete cystectomy, and partial hepatectomy.

The disadvantage of PAIR treatment with the drug albendazole is usually significantly tolerated by the patients. Infections are treated with antibacterial treatment; leak during drainage procedure can cause fever, hypotension, and allergic reactions, but can be expected and well treated with paracetamol, epinephrine injection as intravenous fluid or subcutaneous is administered.

PAIR may be the best treatment for hepatic hydatid cysts, but there is less evidence to continue its use as a drug of choice in the above procedure for patients with uncomplicated cysts [9].

### 6.2 Scolicidal Agents

Protoscolices are larvae of parasites that develop into adults in the host's intestine. In the surgical treatment of human echinococcosis, the outflow of the protocols of living organisms is the most common cause of the recurrence of echinococcosis.

To prevent this problem, a neck killer such as hypertonic salt is used to kill the anterior cervical spine that may spread to the patient's tissues during the operation. However, they may have some unacceptable side effects [10]. Numerous related studies were reviewed [11-15].

### 6.3 Prevention

Avoiding multilocular *E. coli* from wild animal hosts is impractical. So, in infected areas, avoid contact with dogs and foxes. Preventing human infections depends on awareness to improve personal hygiene and environmental sanitation. Monthly praziquantel treatment can be used to prevent infections in dogs that are likely to eat infected rodents.

## 7. DISCUSSION

Mebendazole was the drug of choice to treat echinococcosis. Afterwards, due to its great absorption properties [9].

In an Randomized controlled trial by GilGrande et al., All patients underwent for the surgery: 17 patients did not get albendazole drug treatment, 20 patients were given Albendazole for 1 month, and 20 patients were given the same for about 3 months. 8 cysts (50 percent) in the control, 12 (71 percent) in the Albendazole for one month group, and 15 (93 percent) in the ALB for three months group were not alive ( $P = 0.018$ ).

A research by Keshmiri et al. found similar findings in 28 individuals with 241 cysts who were randomly randomised to receive ALB (3 months) or placebo. When ALB is combined with surgery, the best results are attained [9].

Several studies comparing aggressive surgery and conservative surgery have been published. Despite the limited sample size, Yüksel. observed that cautious surgery was associated with considerably higher recurrence and morbidity rates in their single randomised trial [9].

Almost all types of liver hydatid cysts can be treated safely and effectively with laparoscopic surgery. Large-scale prospective and randomised trials have failed to prove its superiority. (Open laparoscopy).

Percutaneous drainage combined with albendazole is more successful than monotherapy in treating liver hydatid cysts and is both safe and efficacious. Complications, on the other hand, are conceivable. Khuroo and his colleagues [9].

The PAIR treatment appears to be the most widely accepted, but it is primarily compared to conservative surgery rather than drastic surgery in the published research. Only 129 patients with liver hydatidosis treated with PAIR drainage ( $n =$

51), radical surgery ( $n = 62$ ), and conservative surgery ( $n = 34$ ) patients with cysts were studied by Gupta et al. The PAIR procedure was terminated in 11 patients because to inhalation of bile or cystic debris post initial puncture. Following that, the same patients underwent surgery. PAIR as a regular treatment currently has little or no evidence to support it, and more well-designed research are needed before it can be suggested [9].

This review provides evidences to all the queries related to the management of liver hydatid cysts. The limitations of the review are the different surgical methods stated in the published articles [9].

## 8. CONCLUSION

Hepatic hydatid cysts are usually asymptomatic and are usually diagnosed accidentally. The common symptoms are pain in the upper right abdomen and/or upper abdomen. Surgical methods, including conservative and radical treatment, can affect the outcome of liver hydatid cysts. Compared with open surgery for hepatic hydatid cysts, we have shown that laparoscopic surgery can be performed safely even in large cysts, multiple cysts and bile duct cysts [12].

## CONSENT

It is not applicable.

## ETHICAL APPROVAL

It is not applicable.

## COMPETING INTERESTS

Authors have declared that no competing interests exist.

## REFERENCES

1. Regmee S, Maharjan DK, Thapa PB. The Current Protocols in the Management of Hepatic Hydatid Disease. Indian J Surg; 2021. [cited 2021 Jul 16]; Available: <https://doi.org/10.1007/s12262-021-02724-2>
2. Aeberhard P, Fuhrmann R, Strahm P, Thommen A. Surgical treatment of hydatid disease of the liver: an experience from outside the endemic area. Hepatogastro-Enterology. 1996; 43(9):627–36.

3. Botezatu C, Mastalier B, Patrascu T. Hepatic hydatid cyst – diagnose and treatment algorithm. *J Med Life*. 2018; 11(3):203–9.
4. Moro P, Schantz PM. Echinococcosis: A review. *International Journal of Infectious Diseases*. 2009;13(2):125–33.
5. Tai Q-W, Tuxun T, Zhang J-H, Zhao J-M, Cao J, Muhetajiang M, et al. The role of laparoscopy in the management of liver hydatid cyst: a single-center experience and world review of the literature. *Surg Laparosc Endosc Percutan Tech*. 2013;23(2):171–5.
6. Palanivelu C, Senthilkumar R, Jani K, Rajan PS, Sendhilkumar K, Parthasarathi R, et al. Palanivelu hydatid system for safe and efficacious laparoscopic management of hepatic hydatid disease. *Surg Endosc*. 2006;20(12):1909–13.
7. Khatoun S, Talpur A, Shaikh AA, Rehman MUR. Laparoscopic Treatment of Hydatid Cyst of Liver: Outcome at Tertiary Care Hospital. *Journal of Pharmaceutical Research International*. 2020;32(19):164-168. DOI: 10.9734/jpri/2020/v32i1930748.
8. Smego RA Jr, Bhatti S, Khaliq AA, Beg MA. Percutaneous Aspiration-Injection-Reaspiration Drainage Plus Albendazole or Mebendazole for Hepatic Cystic Echinococcosis: A Meta-analysis. *Clinical Infectious Diseases*. 2003;37(8):1073–83.
9. Concepci&ocute, n Gomez i Gavara RL, pez-And&uacute, Jar TBI, Ñez J, Ramia &Aacute M, et al. Review of the treatment of liver hydatid cysts. *World Journal of Gastroenterology*. 2015; 21(1):124–31.
10. Sharafi SM, Sefiddashti RR, Sanei B, Yousefi M, Darani HY. Scolicidal agents for protoscolices of *Echinococcus granulosus* hydatid cyst: Review of literature. *J Res Med Sci*. 2017;22:92.
11. Bayrak M, Altintas Y. Current approaches in the surgical treatment of liver hydatid disease: single center experience. *BMC Surgery*. 2019;19(1):95.
12. Manekk RS, Mehta A. Recurrence of Primary Pulmonary Hydatidosis in the Left Lung with No Hepatic Involvement. *Journal of Evolution of Medical and Dental Sciences-JEMDS*. 2021;10(10):746–8.
13. Andhale A, Acharya S, Devde K, Shukla S. Disseminated Abdomino-Thoracic Hydatidosis Presenting as Mediastinal Syndrome. *Journal of Evolution of Medical and Dental Sciences-JEMDS*. 2021;10(23): 1807–8.
14. Pratapa, Karthik, Sourya Acharya, Yash Gupte, Samarth Shukla. Acute B Virus Hepatitis with Fulminant Hepatic Failure Precipitating Crisis in Sickle Cell Disease. *Journal of evolution of Medical and Dental Sciences-JEMDS*. 2020;9(3): 173–75. Available:https://doi.org/10.14260/jemds/2020/40.
15. Raja KK, Acharya S, Inamdar A, Kumar S. Wilsons Disease Presenting as Acute Fulminant Hepatic Failure. *Journal of Evolution of Medical and Dental Sciences-JEMDS*. 2021;10(16):1185–6.

© 2021 Sharma et al.; This is an Open Access article distributed under the terms of the Creative Commons Attribution License (<http://creativecommons.org/licenses/by/4.0>), which permits unrestricted use, distribution, and reproduction in any medium, provided the original work is properly cited.

*Peer-review history:*

*The peer review history for this paper can be accessed here:*  
<https://www.sdiarticle5.com/review-history/81318>